



## **Somatostatin Infusions Reduce Post-Operative Bile Leak after Hepatopancreatobiliary Surgery: An Observational Preliminary Study**

**Pitiakoudis Michael<sup>1\*</sup>, Zezos Petros<sup>2</sup>, Kouklakis Georgios<sup>2</sup>,  
Fotakis Stelios<sup>1</sup>, Romanidis Konstantinos<sup>1</sup>, Nagorni Eleni-Aikaterini<sup>1</sup>,  
Tsalikidis Christos<sup>1</sup>, Botaitis Sotirios<sup>1</sup>, Iatrou Christos<sup>3</sup>,  
and Simopoulos Constantinos<sup>1</sup>**

<sup>1</sup>*2<sup>nd</sup> Department of Surgery, Democritus University of Thrace, University General Hospital of Alexandroupolis, Dragana, 68100, Alexandroupolis, Greece.*

<sup>2</sup>*Gastrointestinal Endoscopy Unit, Democritus University of Thrace, University General Hospital of Alexandroupolis, Dragana, 68100, Alexandroupolis, Greece.*

<sup>3</sup>*Department of Anesthesiology, Democritus University of Thrace, Greece.*

### **Authors' contributions**

*This work was carried out in collaboration between all authors. Authors PM, RK, TC and IC performed surgeries and attended the postoperative situation of the patients. Authors ZP, KG, NEA and BS designed the study, wrote the protocol, and wrote the first draft of the manuscript. Author FS performed the statistical analysis. Author SC reviewed the manuscript and gave the final commentaries. All authors read and approved the final manuscript.*

**Research Article**

**Received 15<sup>th</sup> November 2012**  
**Accepted 26<sup>th</sup> January 2013**  
**Published 18<sup>th</sup> May 2013**

### **ABSTRACT**

**Background:** Bile leak is a complication of hepatopancreatobiliary surgery and results from injury to the bile ducts. Treatment usually consists of percutaneous drainage combined with the placement of a biliary stent or a nasobiliary draining tube in the biliary tree via endoscopic retrograde cholangiopancreatography. Animal experiments and studies in humans have shown that somatostatin reduces bile secretion.

**Objective:** To evaluate the efficacy of somatostatin as a conservative monotherapy for the successful management of mild to moderate post-operative bile leak.

**Place and Duration of Study:** 2<sup>nd</sup> Department of at the University General Hospital of Alexandroupolis, during the period of 2010 and 2012.

\*Corresponding author: Email: [mpitiak@med.duth.gr](mailto:mpitiak@med.duth.gr);

**Patients and Methods:** Fifteen patients (11male/4 female) with a mean age of 70.1±4.2 years who developed uncomplicated post-operative bile leak with a daily output ranging from 100ml to 800ml were included in the study. Eleven patients were operated for benign diseases of the liver and biliary tract, while the rest 4 patients for pancreatic or biliary tract malignancies. Somatostatin was administered intravenously to all patients in continuous infusions of 3000µg/12hours until complete recession of bile leak along with total parenteral nutrition.

**Results:** Somatostatin treatment was successful in 14 patients (93.3%), with success being defined as the complete cessation of bile leak. Overall, mean duration of bile leak was 13.8±3.9 days. No major adverse reactions or complications were observed and no patients died.

**Conclusions:** Somatostatin appears to be effective in the treatment of post-operative bile leak. The efficacy of somatostatin is observed both in patients with benign or malignant disease.

*Keywords: Somatostatin; postoperative; bile leak; hepatopancreatobiliary surgery.*

## ABBREVIATIONS

*ERCP: Endoscopic retrograde cholangiopancreatography; CT: computerized tomography; Tc-HIDA; Tc99m-hepatobiliary iminodiacetic acid scanning; TPN; total parenteral nutrition; BDI; bile duct injury; HPB; hepatopancreatobiliary.*

## 1. INTRODUCTION

Bile leak is a complication of hepatopancreatobiliary surgery and results from injury to the bile ducts. In general it is less common than stenosing injuries to the bile ducts. Bile leaks usually originate from the stump of the cystic duct, a transected aberrant right hepatic duct or lateral injury to the main bile duct itself. The incidence of bile leak whether internal or infrequently external, has been increased to approximately 0.3%, with the establishment of laparoscopic cholecystectomy [1,2].

Roughly one quarter of iatrogenic bile duct injuries are recognized and repaired intraoperatively. The rest are usually diagnosed within a month following the operation. Patients with bile leaks usually present with pain, fever and mild hyperbilirubinemia biliary peritonitis. Less commonly bile may leak out of a surgical drain or through the incision-wound. Diagnosis is confirmed by ultrasound, computerized tomography (CT) scanning of the abdomen or Tc99m-hepatobiliary iminodiacetic acid (Tc-HIDA) scanning [1,2].

Management of bile leaks, depending on the severity of the clinical presentation and the status of the patient. Treatment usually consists of percutaneous drainage combined with the placement of a biliary stent or a nasobiliary draining tube in the biliary tree via Endoscopic retrograde cholangiopancreatography (ERCP), intended to decompress the biliary vessels, while surgery is indicated for more complicated cases [3-7].

Somatostatin was isolated in 1974 as an inhibitor of growth hormone release [8]. Subsequent studies helped to identify numerous further properties of somatostatin, including its activity as a neurotransmitter, as an inhibitor of gastrointestinal motility, as well as an inhibitor of the secretion of gastrointestinal hormones [9-12].

Animal experiments and studies in humans have shown that somatostatin reduces bile secretion [10-13]. In humans, this action has been attributed mainly to an effect on the bile-acid dependent canalicular bile flow and secondarily to an effect on ductular secretion [10,11].

The inhibitory effect of somatostatin on bile secretion is now indisputable, while efficacy to reduce bile secretion in clinical practice has been reported in a case by Hillenbrand [14] and in one observational study of seven patients with malignant biliary obstruction and external transhepatic biliary drainage, by Andersen et al. [15].

The aim of this study was to investigate the efficacy of somatostatin, as a non-invasive conservative monotherapy, besides total parenteral nutrition, in the management of mild to moderate post-operative bile leak.

## **2. MATERIALS AND METHODS**

Patients who developed mild to moderate, without any other complications, post-operative bile leak were included in this study. Patients were recruited from the Second Department of Surgery at Democritus University of Thrace. The study was conducted in accordance with the Helsinki Declaration of Human Rights, it was approved by the responsible Ethical Committee and informed consent was obtained from all patients.

Bile leak was defined as postoperative leakage of bile, either through drainage tubes or through biliary-cutaneous fistulae. Duration of bile leak was determined as the number of days of bile leakage from the initial occurrence until its complete recession, or until other means of management were implemented.

Despite the fact that the patients' group is very heterogenous and some cases may need operative repair, patients with volumes of persisting bile leakage for more than 72 hours post-operatively ranging from 100 to 800 ml per day and whose condition was not considered critical were considered eligible for inclusion in the study. Severe peritonitis and/or sepsis, poor general condition of the patient and bile leak volumes of less than 100ml per day or above 800ml per day were set as exclusion criteria. On the other hand, there was not the possibility to define the point of bile leak as it is a difficult and non-specific procedure even if it is carried out with Magnetic resonance cholangiopancreatography as it is not a dynamic examination. So, this factor was not included to the patients' criteria for inclusion in the study.

Somatostatin was administered to all patients by continuous infusions at a dose of 250 µg per hour (3000µg/12h). Treatment was continued until complete recession of bile leak through the drainage tube or healing of the fistula, excluding a proximal biliary obstruction. In our study the daily cost treatment was lower than 80 Euros while an uneventful ERCP would cost much more plus the equipment, adjuvant medications, staff work etc. Moreover, in the case of post-ERCP complications or re-operation the costs are multifold. Thus somatostatin monotherapy could be a safe, effective and lower-cost treatment option in a subgroup of patients with post-operative bile leak. Additionally, patients received total parenteral nutrition (TPN) throughout treatment period, while enteral nutrition was withheld, in order to avoid stimulation of bile secretion. Furthermore, we administered Omeprazole simultaneously with somatostatin during their hospitalization. According to the protocol of this study, the administration of somatostatin was recessed the bile leak without other simultaneous therapeutic managements such as percutaneous drainage, ERCP or biliary stents. If no

improvement of bile leak or deterioration clinical condition was noted during 2 weeks of conservative treatment patients were treated with ERCP as appropriate.

Statistical analyses were performed using the SPSS for Windows package (version 11.0, SPSS, Chicago, IL). For the statistical analysis continuous data are presented as mean values along with  $\pm$ SD and categorical data are presented as proportions. Comparisons of proportions were assessed by the Fisher's exact test, while comparisons of continuous data were analysed by the Mann-Whitney U test. The level of significance was set at 0.05.

### 3. RESULTS

Fifteen patients (11 men and 4 women; mean age of  $70.1\pm 4.2$  years) with a post-operative bile leak were included in this study. Eleven patients had been operated for benign diseases of the liver and biliary tract, while 4 patients suffered from pancreas or biliary tract malignancies (Table 1).

**Table 1. Demographics, indications for surgery and operative details in patients with post-operative bile leak**

<b>Patient age (years<math>\pm</math>SD)</b>	<b>70.1<math>\pm</math>4.2</b>
<b>Sex (male/female)</b>	11/4
<b>Indications for surgery</b>	
<u>Benign</u>	11
<i>Symptomatic cholelithiasis</i>	4
<i>Choledocholithiasis</i>	2
<i>Cholecystitis</i>	3
<i>Empyema</i>	1
<i>Hydatid cyst</i>	1
<u>Malignant</u>	4
<i>Pancreatic carcinoma</i>	3
<i>Bile duct cancer</i>	1
<b>Elective/emergency surgery</b>	15/0
<b>Open/laparoscopic surgery (cholecystectomy)</b>	7/8

*Values expressed as raw data (%) or mean (range)*

Eleven patients with benign biliary diseases developed post-operative bile leak; 8 after laparoscopic and 2 after open cholecystectomy, with or without intraoperative exploration of the biliary duct and 1 after partial decapsulation and excision of a hepatic hydatid cyst. Six patients presented with bile leak from the stump of the cystic duct. One patient who had undergone a subtotal cholecystectomy with placement of a large-bore drainage tube in the gallbladder remnant presented with bile leak from the gallbladder stump two days after the removal of the drainage tube. Two patients developed bile leak which originated from unrecognised iatrogenic bile duct injuries (BDI), while in one case the leak originated from a duct of Luschka as evidenced by the MR-cholangiography studies (Table 2). Finally, 1 patient developed bile leak from the site of the hepatic hydatid cyst decapsulation. Of the 4 patients with malignancy, three patients presented with anastomotic bile leakage after palliative biliary-enteral anastomosis. The fourth patient presented with a biliary fistula after the removal of the percutaneous drainage of a cystic malignant tumor of the liver (Table 2).

**Table 2. Peri-operative details in patients with post-operative bile leak**

<b>Surgery</b>	
Elective	15
Emergency	0
<b>Surgery</b>	
Open	7
Laparoscopic*	8
<b>Origin of leak</b>	
<u>Benign diseases</u>	11
<i>Cystic duct stump</i>	6
<i>Gallbladder stump</i>	1
<i>Luschka</i>	1
<i>Other BDI</i>	2
<i>Liver parenchyma**</i>	1
<u>Malignant diseases</u>	4
<i>Anastomosis</i>	3
<i>Liver parenchyma</i>	1
<b>Somatostatin treatment</b>	15
<b>Effective</b>	14
Benign disease	10/11 (91%)
Malignancy	4/4 (100%)
<b>Adverse events</b>	0

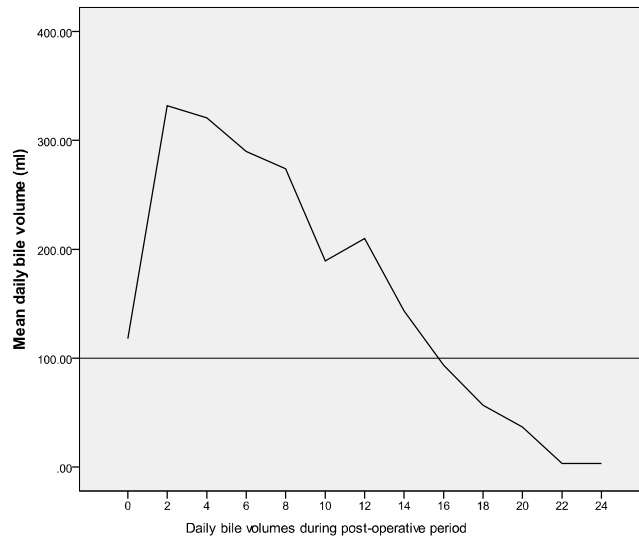
*BDI: bile duct injury, Values expressed as raw data (%).*

*\*cholecystectomies.*

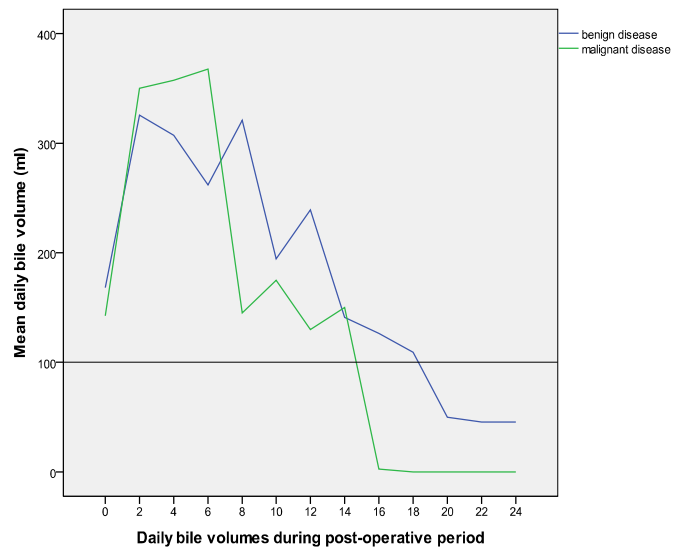
*\*\* hydatid cyst excision.*

Overall, conservative treatment of post-operative bile leak was successful in 14 patients out of 15 patients treated (93.3%). Treatment was successful in 10 out of 11 patients (90.9%) with benign disease and in all four patients (100%) with malignant disease (Table 2). Treatment failure was observed in one patient only, who presented with leakage from the stump of the cystic duct, refractory to the management with somatostatin, omeprazole and TPN. Although ERCP with sphincterotomy and stent placement were performed in this patient the bile leak did not improve and a subsequent surgical repair was the final curative treatment. Somatostatin was well-tolerated by all patients. No adverse events or complications were observed during treatment.

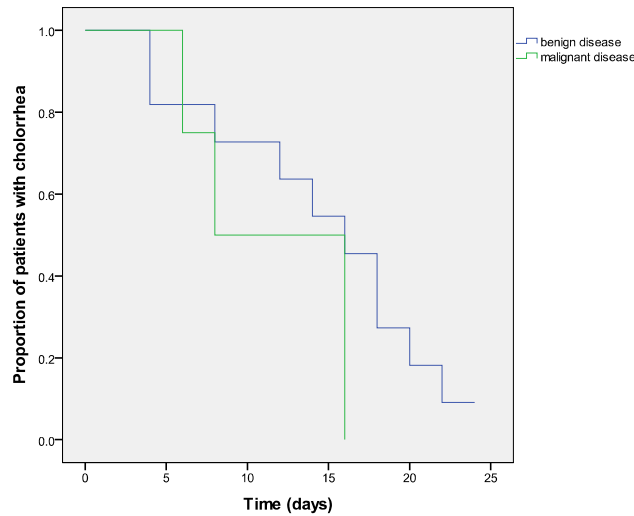
An improvement of bile leak was observed in all but one patient treated with somatostatin with a gradual decrease in overall daily bile volume (Fig. 1). Mean bile volume below 100ml was noted in the end of the 2nd week (day 16) of treatment (Figs. 1, 2 and 3). There were no significant differences in bile leak, regarding daily bile volume and duration of bile leakage, between benign and malignant disease (Figs. 1, 2 and 3).



**Fig. 1. Overall patient mean daily volume of post-operative bile leak, since the induction of Somatostatin treatment. (0=post-operative day 3)**



**Fig. 2. Overall patient mean daily volume of post-operative bile leak in groups of patients with benign and malignant disease, since the induction of Somatostatin treatment. (0=post-operative day 3)**



**Fig. 3. Kaplan-Meier plot of the time to cessation of post-operative bile leak during the somatostatin treatment for a period of four weeks. (0=post-operative day 3)**

#### 4. DISCUSSION

Bile duct injury with ensuing bile leakage is a serious complication of hepatopancreatobiliary (HPB) surgery. With the advent of laparoscopic cholecystectomy the incidence of bile duct injuries (BDIs) and subsequent bile leak has increased [1]. Unfortunately, bile duct injury may be overlooked during surgery [2]. In open HPB surgery, usually for malignancies of the pancreas, liver or extrahepatic bile ducts, BDIs are less commonly overlooked and bile leak mostly originates from biliary-enteral anastomotic failure.

Bile leak can be managed endoscopically by means of ERCP – sphincterotomy together with the placement of a biliary duct stent or a nasobiliary catheter [3,4]. However, depending on factors such as the underlying pathology, the presence or absence of sepsis, the patient's condition and the department's experience, surgical repair may still be necessary [1,2,5,6]. This may be accomplished by both a minimally invasive or traditional approach.

Bile leak of a volume smaller than 200 ml per day can be treated expectantly, with excellent results in most of the cases [3,6]. On the other hand, large volumes of bile, exceeding 800-1000ml/day or the presence of abdominal sepsis present an indication for aggressive management of bile leak [3]. Post-operative bile leaks, whether anastomotic or traumatic in origin are serious but fortunately not common complications. When they do arise they are associated with considerable morbidity and mortality. Moreover they require, when treated conservatively, a lengthy stay in the hospital. Lengthy hospital stays, are of course in turn associated with increased cost and morbidity [3].

This study showed that somatostatin monotherapy together with TPN may be an effective conservative treatment for the management of post-operative bile leak, aimed at the subgroup of patients whose bile leak volume is large enough to preclude expectant treatment but who do not present with excessive leakage (over 800ml per day) or with complications such as sepsis or peritonitis, thus allowing the time for a lengthier and non

invasive management. Somatostatin could be a treatment of choice in the management of bile leak as it did not cause any complications excluding proximal biliary obstructions such as large collection compressing the bile duct, according to the patients' follow-up, too. Furthermore, somatostatin can be used as an adjunct treatment to endoscopy and stenting, in the subset of patients requiring more immediate resolution, aimed at reducing the days of post-intervention bile leak. Overall, treatment was successful in 93.3% of our cases. In practical terms this means that the addition of somatostatin infusions to the treatment of bile leaks, in a very specific subset of patients reduces bile secretion and stops the bile leak in a more timely fashion, without the need for costly and risky interventions. If this is so, then it should reflect positively, as it did in our case series, on length of hospitalisation, cost of treatment and foremost on associated morbidity.

It is clear that somatostatin is no panacea in the treatment of bile leaks. In patients presenting with very small volume bile leak, less than 100 ml/day, the addition of somatostatin is probably not needed. On the other hand, in patients presenting with very large volumes of bile leak and especially those presenting with peritonitis and/or sepsis, it is probably wiser to intervene early. In the literature, only Hillenbrand reported one case of successful treatment of a post-operative biliary fistula with somatostatin [13].

A case could be made that somatostatin treatment may be as effective and less risky than endoscopic management of post-operative bile leak in patients who lie in between these two extremes with medium-volume bile leak (100-800ml/day). It stands to reason that one should set clear indications for recognising treatment failure and the need to proceed with more aggressive means. In our series the indication was the persistence of bile leak in one case. A further question that presents itself is whether somatostatin could be of benefit as an adjuvant for those patients treated primarily by endoscopy.

Although this is a very heterogeneous group of patients that in one hand might need ERCP or even operative repair, while on the other hand minor injuries and low output fistula might even heal conservatively, our study hereby hints that somatostatin therapy together with TPN treatment was equally efficacious both in patients with benign and in those with malignant disease. Indeed, treatment efficacy in terms of success rate and duration of bile leak was comparable in these two conditions. Unfortunately data on the use of somatostatin in malignant diseases of the biliary tract are scarce. In a previous trial, the somatostatin treatment of seven patients with common bile duct occlusion due to unresectable periampullary pancreatic cancer, demonstrated a significant reduction in daily bile loss through palliative external biliary drainage [14]. However, this study is an observational case series, comprised of a small number of patients, who fit the needed profile. Moreover, our study is non-randomized with limited sample size. More studies are needed to support the evidence of the use and efficacy of somatostatin in speeding up and eventually increasing the success rate of healing of biliary fistulas. For this case, randomized controlled trials where the biliary leakage treatment in stable, without peritonitis and not severely septic patients, is randomized to either the traditional conservative treatment, including Percutaneous drainage +/- ERCP +/- biliary stent on one hand and to the aforementioned traditional conservative treatment plus somatostatin infusions as an adjunct could provide useful data if the latter (somatostatin) group will show a significantly higher success rate of fistula healing and/or a significantly faster resolution of biliary leak.



#### **4. CONCLUSION**

In conclusion, this study suggests that somatostatin monotherapy plus TPN treatment is an effective and safe treatment for the management of mild to moderate post-operative bile leak without septic complications. Treatment efficacy is equal in patients with benign and in those with malignant disease. These findings indicate a potential role for somatostatin in the management of post-operative bile leak, although further randomized controlled prospective studies with more homogenous groups of patients are required to evaluate the long-term efficacy of somatostatin in ceasing the bile leaks.

#### **CONSENT**

Written informed consent was obtained from the patient for publication of this case report and accompanying images.

#### **ETHICAL APPROVAL**

All authors hereby declare that all experiments have been examined and approved by the appropriate ethics committee and have therefore been performed in accordance with the ethical standards laid down in the 1964 Declaration of Helsinki.

#### **COMPETING INTERESTS**

The authors declare that they have no competing interests.

#### **REFERENCES**

1. Nuzzo G, Giuliani F, Giovannini I, Ardito F, Acapito FD', Vellone M, et al. Bile duct injury during laparoscopic cholecystectomy. Results of an Italian National Survey on 56591 cholecystectomies, *Arch Surg.* 2005;140(10):986-992.
2. Kimura T, Suzuki K, Umehara Y, Kawabe A, Wada H. Features and management of bile leaks after laparoscopic cholecystectomy, *J Hepatobiliary Pancreat Surg.* 2005;12(1):61-64.
3. Ahmad F, Saunders RN, Lloyd GM, Robertson GSM. An algorithm for the management of bile leak following laparoscopic cholecystectomy, *Ann R Coll Surg Engl.* 2007;89(1):51-56.
4. Pinkas H, Brady PG. Biliary leaks after laparoscopic cholecystectomy: time to stent or time to drain, *Hep Panc Dis Int.* 2008;7(6):628-632.
5. Zerem E, Omerovic S. Minimally invasive management of biliary complications after laparoscopic cholecystectomy, *Eur J Int Med.* 2009;20(7):686-689.
6. Spanos CP, Syrakos T. Bile leaks from the duct of Luschka (subvesical duct): a review, *Lang Arch Surg.* 2006;391(5):441-447.
7. McPartland KJ, Pomposelli JJ. Iatrogenic biliary injuries: classification, identification, and management, *Surg Clin North Am.* 2008;88(6):1329-1343.
8. Brazeau P, Guillemin R. Somatostatin: newcomer from the hypothalamus, *N Engl J Med.* 1974;290(17):963-964.
9. Magnusson I, Einarsson K, Angelin B, Nyberg B, Bergström K, Thulin L. Effects of somatostatin on hepatic bile formation, *Gastroenterology.* 1989;96(1):206-212.
10. Nyberg B. Bile secretion in man. The effects of somatostatin, vasoactive intestinal peptide and secretin, *Acta Chir Scand Suppl.* 1990;557:1-40.

11. Nyberg B, Angelin B, Einarsson K. Somatostatin does not block the effect of vasoactive intestinal peptide on bile secretion in man, *Eur J Clin Invest.* 1992;22(1):60-66.
12. Ricci GI, Fevery J. Somatostatin inhibits the effect of secretin on bile flow and on hepatic bilirubin transport in the rat, *Gut.* 1989;30(9):1266-1269.
13. Gong AY, Tietz PS, Muff MA, Splinter PL, Huebert RC, Strowski MZ, et al. Somatostatin stimulates ductal bile absorption and inhibits ductal bile secretion in mice via SSTR2 on cholangiocytes, *Am J Physiol Cell Physiol.* 2003;284(5):1205-1214.
14. Hillenbrand F. Treatment of a biliary fistula with somatostatin, *Chirurg.* 1982;53(12):802-803.
15. Andersen HB, Petronijević L, Giese B, Mygind T, Burcharth F. Somatostatin reduces bile secretion and loss of bile constituents in patients with external biliary drainage, *HPB Surgery.* 1996;9(4):229-233.

---

© 2013 Michael et al.; This is an Open Access article distributed under the terms of the Creative Commons Attribution License (<http://creativecommons.org/licenses/by/3.0>), which permits unrestricted use, distribution, and reproduction in any medium, provided the original work is properly cited.

*Peer-review history:*

*The peer review history for this paper can be accessed here:*  
<http://www.science-domain.org/review-history.php?iid=205&id=12&aid=1403>