



Management of calcular anuria in adults caused by ureteric stones: By using of ureteroscopy and holmium laser

Mohammad S. Abdel-Kader

To cite this article: Mohammad S. Abdel-Kader (2011) Management of calcular anuria in adults caused by ureteric stones: By using of ureteroscopy and holmium laser, Arab Journal of Urology, 9:3, 179-182, DOI: [10.1016/j.aju.2011.09.004](https://doi.org/10.1016/j.aju.2011.09.004)

To link to this article: <https://doi.org/10.1016/j.aju.2011.09.004>



© 2011 Arab Association of Urology



Published online: 05 Apr 2019.



Submit your article to this journal [↗](#)



Article views: 211



View related articles [↗](#)



Citing articles: 1 View citing articles [↗](#)



Arab Journal of Urology
(Official Journal of the Arab Association of Urology)

www.sciencedirect.com



STONES/ENDOUROLOGY

ORIGINAL ARTICLE

Management of calcular anuria in adults caused by ureteric stones: By using of ureteroscopy and holmium laser ☆

Mohammad S. Abdel-Kader *

Urology Department, Faculty of Medicine, South Valley University, Qena, Egypt

Received 10 July 2011, Received in revised form 14 September 2011, Accepted 22 September 2011

Available online 17 November 2011

KEYWORDS

Anuria;
Adults;
Ureteric calculi;
Holmium laser

Abstract *Purpose:* To present our clinical outcomes in managing of anuria in adult patients caused by ureteral calculi by using of ureteroscopy and holmium laser.

Materials and methods: Nineteen patients presented with calcular anuria with age between 19 and 48 years. The presentation was anuria with serum creatinine levels were 2–5.5 mg% (mean 3.5) and hyperkalemia in nine patients (5.2–6.1 mmol/L). There were bilateral ureteric stones in 14 (73.7%) and unilateral in five (26.3%) with single functioning kidney. Thirty-three ureteroscopic procedures were performed for 19 patients including bilateral ureteroscopy in 14. Laser lithotripsy was delivered using holmium laser via 356 µm laser fibre, with energy (1–1.2 J) and pulse rate (10 Hz). Post-operatively, monitoring of urine output, serum creatinine and K levels was done until normal values were obtained.

Results: Ureteroscopy was performed for all 19 patients (33 procedures), but laser lithotripsy was done successfully in 30 procedures. The operative time was 46 min (25–70). The successful fragmentation rate was (100%). The stone-free rate was 90.9%. There were mucosal abrasions in 6 (31.5%), and mild to moderate haematuria in 9 (47.4%), and high fever in two patients (10.5%). Serum creatinine and potassium levels returned to normal within 7–10 days. Urine output gradually reached normal level within a week.

Conclusions: Ureteroscopy and holmium laser lithotripsy represent an effective and safe modality for treatment of anuria caused by ureteral calculi.

© 2011 Arab Association of Urology. Production and hosting by Elsevier B.V. All rights reserved.

☆ This journal is partially supported by Karl Storz GmbH. That support had no influence on the peer-review of this paper, which was entirely independent of Karl Storz.

* Tel.: +20 165459050; fax: +20 965226432.

E-mail address: Moh6789@yahoo.com.

Introduction

Post renal anuria is mostly due to obstruction of urinary tract and the most common cause of urinary obstruction is ureteral calculi [1]. The treatment of ureteral stone varies from simple



Production and hosting by Elsevier

clinical observation and waiting for spontaneous passage to use of refined endourologic techniques to extract the stone. The introduction of minimally invasive procedures provides a less painful and faster recovery, as well as better results, justifying the preference for endourologic techniques over conventional surgeries. Advances in ureteroscopic technology as well as the introduction of the holmium: YAG laser have improved the ureteroscopy stone-free rate while decreasing the risk of complications [1].

The patient presented with acute urinary obstruction in need for urgent drainage of the urinary tract either by ureteral stenting or percutaneous nephrostomy.

Here in, we present our clinical outcomes in managing of anuria in 19 adult patients caused by ureteral calculi by using of ureteroscopy and holmium laser.

Material and methods

Between April 2005 and December 2007, 19 patients (12 males and seven females) presented to our department with calcular anuria. The age ranged between 19 and 48 years (mean 33 years).

The main complaint was anuria for 24–72 h in all patients. The other clinical presentations included unilateral or bilateral renal pain in all patients, hypertension in 13 patients (68%) and nausea and vomiting in 10 patients (52.6%). Serum creatinine levels were 2–5.5 mg% (mean 3.5) and blood urea was 50–105 mg% (mean 72). There was hyperkalemia in nine patients (5.2–6.1 mmol/L). Decompensated patients those in needs for urgent dialysis were excluded from the study (patients with severe hyperkalemia, severe metabolic acidosis, pericarditis or disturbed conscious level) and managed properly after efficient dialysis.

All patients were subjected to plain X-ray, non-enhanced CT and abdominal ultrasonography (US) to estimate the stone site and size and determine the degree of back pressure caused by the stones.

There were bilateral ureteric stones in 14 (73.7%) patients and unilateral ureteric stone in five (26.3%) patients with single functioning kidney (three with nephrectomized other kidney and two with non-functioning other kidney). For a total 33 stones, the stone distribution was 15 in distal ureter, seven in middle 1/3 ureter and 11 in upper 1/3 ureter. The stone size ranged from 0.9 to 2.4 cm (mean 1.3) estimated by plain X-ray and non-enhanced CT, Table 1.

Thirty-three ureteroscopic procedures were performed for 19 patients by using of 7.5 Fr semirigid ureteroscope (Storz) with 4 Fr working channel. Fourteen patients with bilateral ureteric stone underwent bilateral same-session ureteroscopy.

Spinal anaesthesia was used for all patients then placed in lithotomy position. The procedure was started with urethrocytoscopy and insertion of guide wire in the ureteric orifice then, dilatation by balloon dilator. Next, the ureteroscope was inserted and guided by the wire and carefully advanced till the stone to estimate its size visually, then, according to stone size and its compatibility with the ureteric lumen we had to decide to use intra-corporeal lithotripsy by laser. Laser lithotripsy was delivered using holmium laser via 356 µm laser fibre in pulsed mode, with energy between 1 and 1.2 J and pulse rate of 10 Hz.

Fragments less than 2 mm were left as they can pass, but larger fragments were extracted by dormia or stone grasper. Ureteral stenting by 5–7 double j (DJ) stents was performed at the end of procedure for all patients.

Post-operatively, all patients were evaluated by monitoring urine output, serum creatinine and blood urea, and serum K daily until normal values were obtained. Plain KUB film and US were performed at 2nd days post-operatively and during the follow-up visits (after 2 weeks and 4 weeks). DJ stents were removed after 4 weeks under local anaesthesia in the urology out patient clinic.

Results

Ureteroscopy was performed for all 19 patients (33 procedures), but laser lithotripsy was done successfully in 30 procedures (Fig. 1a, b) where stone migration to the kidney occurred in three events during upper ureteric stone manipulation, and DJ stents were left in these ureters and the migrated stones were subjected to ESWL after normalization of serum creatinine. Bilateral same-session ureteroscopy and laser lithotripsy (Fig. 2a, b) were done successfully in 14 patients (73.7%).

The mean operative time was 46 min (range, 25–70 min). The successful fragmentation rate by using holmium laser was (100%) [30/30]. The stone-free rate was (90.9%) [30/33].

There were no major intra-operative complications (e.g. ureteral perforation or avulsion). There were mucosal abrasions in 6 patients (31.5%), and mild to moderate haematuria in nine patients (47.4%) which spontaneously resolved within 24 h and did not necessitate blood transfusion. Post-operatively, there was high grade fever in two patients (10.5%) which had returned to normal within 4 days after receiving maximum dose and intravenously injected 3rd generation cephalosporin antibiotic.

Post-operative monitoring of urine volume revealed post-obstructive diuresis in all patients with urine volume 3000–6500 cc/24 h, but the urine output gradually decreased to reach

Table 1 Stone location, number, size and stone free rate.

Stone location	Stone number (<i>n</i> = 33) ^a	Stone size (cm)	Stone-free rate
Lower ureter	15	0.9–1.4	100%
Middle ureter	7	1–2.2	100%
Upper ureter	11	1.3–2.4	9/11 (81.8%) ^b

^a Unilateral stones in five patients (26.3%) and bilateral stones in 14 patients (73.7%), for a total of 33 stones in ureters.

^b There was upward migration of upper ureteric stones in three.

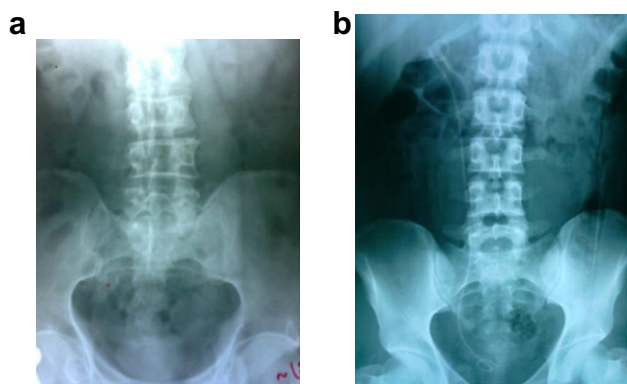


Figure 1 (a) Preoperative KUB of a patient with stone middle 1/3 right ureter and left non-functioning kidney. (b) Post-operative KUB after ureteroscopy and laser treatment, DJ stent was left.

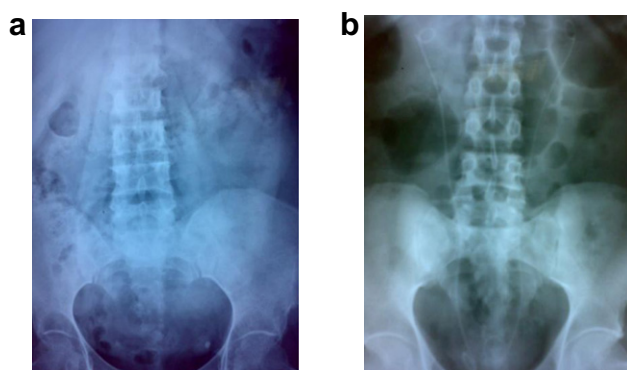


Figure 2 (a) Preoperative KUB of a patient with bilateral lower ureteric stones. (b) Post operative KUB after bilateral same-session ureteroscopy and laser treatment and bilateral DJ insertion.

normal level (1500–2000 cc/24 h) within the 1st week post-operatively. Also, serum creatinine, blood urea and K levels returned to normal levels within 7–10 days.

Discussion

Today, acute kidney injury (AKI) is considered the correct nomenclature for the clinical disorder formerly termed 'acute renal failure' (ARF). AKI is a common clinical problem in critically ill patients that is associated with increased morbidity and mortality. Post renal anuria is a urologic emergency that must be managed rapidly and carefully; otherwise the glomerular filtration rate will be declined rapidly, with rise of blood urea and serum creatinine and water–electrolytes imbalance. Then a series of symptoms in other organs will be evident and lastly multiple organs failure will result and the patient's life will be threatened [2].

There is no evidence of renal deterioration after holmium laser lithotripsy. Laser related complications occur in less than 1%. Stone-free rates from holmium laser lithotripsy are greater than 90% for ureteral calculi, and 67–84% for renal calculi [3].

Because of all types of stones absorb the holmium energy; this laser can be used to fragment all stone types, including

the hard cystine and calcium oxalate monohydrate stones. The holmium YAG laser was unique in its ability to fragment all types of calculi effectively and safely. It fragments stones with an ablative effect. Volume of stones is removed in dust like particles during the fragmentation procedure [4].

The safety and efficacy of the holmium laser as an endoscopic lithotrite have been confirmed in different series [5–7].

Lee and Bagly reported that ureteroscopy should be safe in regard to renal function: there is no puncture, as in PCNL, and no shockwaves directed to renal parenchyma, as in ESWL. However, other potential mechanisms of injury as excessive irrigation may generate enough pressure in the kidney to cause pyelovenous backflow and damage the renal parenchyma and thermal injury caused by the energy of the laser. However, this is unlikely, as frequent irrigation should dissipate the heat energy, so ureteroscopic laser lithotripsy has no harmful impact on renal function in patients with mild to moderate renal insufficiency [8].

Many authors reported their experiences with using of ureteroscopy and holmium laser for treating of ureteric stones in patients with acute renal injury. In one study, the successful fragmentation rate was 95.5% with no major intra-operative complications and normal function returned within 7 days [9]. In another report, the successful fragmentation rate was 93.3% [10].

In a recent Chinese study, Tang and coworkers reported a success rate of 92.3% of ureteroscopic holmium laser lithotripsy in the treatment of 13 patients with ureteral calculi associated with acute renal failure [11].

Safwat et al. also reported that 26 patients with renal insufficiency, including six patients with obstructive anuria, were rendered stone free with ureteroscopic laser lithotripsy, and this 100% success rate with ureteroscopic laser lithotripsy confirms that it is a safe and effective modality of intra-corporeal ureterolithotripsy in patients with renal impairment and even in selected patients with obstructive anuria [12].

In our study, the successful fragmentation rate was 100% with no major intra-operative complications. The stone-free rate was 90.9% as there was stone upward migration in three patients with upper ureteric stones. The overall stone-free rate was 100% after 4 weeks follow-up. (The overall stone-free status was defined as the complete absence of detectable stone fragments by either endoscopic visualization or radiologic evaluation at 4 weeks, post-operatively.) Urine output, renal function tests and K levels returned to normal level within 7–10 days.

Some authors stated that in comparison with unilateral ureteroscopy, no difference were found with bilateral same-session ureteroscopy with regard to complication rate (6.7%) or stone-free rate (80%) and concluded that bilateral same-session ureteroscopy is a safe and effective procedure in the management of bilateral ureteral stones. Bilateral same-session ureteroscopy can prevent frequent surgeries and anesthesia and reduce hospital stay. Proper patient selection, ample experience of surgeon, and appropriate instruments, all reduce complications and increase treatment success [13]. In our study bilateral same-session ureteroscopy and laser lithotripsy were done successfully (an operation was regarded as successful when no residual fragments were larger than 2 mm in size and no additional procedure was required) in 14 patients (73.7%) with minor complications such as mucosal abrasions and mild to moderate haematuria.

Ureteroscopy is relatively a complication free procedure. However if complications do occur they may be related to the procedure itself. The ureteroscopy has variable complications (9–20%) including bleeding, ureteral perforation, false passage, urinoma, strictures and, in a few cases, ureteral avulsion [14].

Low ureteroscopic complication rates are likely due to the advent of smaller-diameter rigid ureteroscopes and more liberal use of flexible devices, complications such as perforation and stricture are directly associated with ureteroscope diameter [15]. We had not such complications in our patients. To reduce complications, we should use safety guide wire in all of the cases and in those with excessive manipulation, ureteral stents are recommended.

Ureteral stents play a major role in wide rang of situations where urinary drainage is needed.

Stenting after ureteroscopy has been recommended to prevent the development of ureteral stricture, facilitates passage of stone fragments and promotes ureteral healing, however few prospective randomized trials have recently been reported in the literature, and all showed no difference in stone-free status between stented and nonstented groups [16].

Safety indications following endoscopic procedures include ureteric oedema, perforation, steinstrasse, history of renal impairment and solitary or transplanted kidney [17].

Despite that post ureteroscopy stenting is not routine, in our study stenting was mandatory to prevent post-operative ureteral obstruction by stone gravils or oedema, and as we need long time for drainage of the kidney till improvement of the renal functions, we used DJ stents instead of ureteric catheter that used only for 2–3 days post-operatively, and also it is not suitable for patients with migrated upper ureteric stones that were treated by ESWL.

Proximal calculus migration during ureteroscopy remains a significant problem. Stone retropulsion during intra-corporeal lithotripsy occurs in 5% to 40% of cases. The risk of retropulsion is influenced by the pressure of the irrigant fluid, type of energy source used for lithotripsy, site and degree of calculus impaction, and degree of proximal ureteral dilation [18]. New instruments such as the Accordion, Stone Cone, and NTrap have been developed to prevent the retropulsion of ureteral stones and enables safe extraction of stone fragments during ureteroscopic lithotripsy [19].

The limitations of the study include its retrospective nature with potential selection bias, the small number of patients and the low evidence based level.

Conclusions

Ureteroscopy and holmium laser lithotripsy represent an effective and safe modality for treatment of patients with acute renal injury that is caused by ureteral calculi.

Conflict of interest statement

There is no conflict of interest with any people or organizations.

References

- [1] Scarpa RM, De Lisa A, Porru D, Usai E. Holmium: YAG laser ureterolithotripsy. *Eur Urol* 1999;**35**:233.
- [2] Praught ML, Shlipak MG. Are small changes in serum creatinine an important risk factor? *Curr Opin Nephrol Hypertens* 2005;**14**:265–70.
- [3] Teichman Joel MH. Laser lithotripsy. *Curr Opin Urol* 2002;**12**(4):305–9.
- [4] Delvecchio FC, Preminger GM. Endoscopic management of urologic disease with the holmium laser. *Curr Opin Urol* 2000;**10**:233–7.
- [5] Grasso M. Complications of ureteropyloscopy. In: Taneja SS, Smith RB, Ehrlich RM, editors. *Complications of urologic surgery*. 3rd ed. Philadelphia: WB Saunders; 2001. p. 268–76.
- [6] Hollenbeck BK, Schuster TG, Faerber GJ, Wolf JS. Flexible ureteroscopy in conjunction with in situ lithotripsy for lower pole calculi. *Urology* 2001;**58**:859–63.
- [7] Sofer M, Watterson JD, Wollin TA, et al. Holmium :YAG laser lithotripsy for upper urinary calculi in 598 patients. *J Urol* 2002;**167**:31–4.
- [8] Lee DI, Bagley DH. Long term effects of ureteroscopic laser lithotripsy on glomerular filtration rate in the face of mild to moderate renal insufficiency. *J Endourol* 2001;**15**:715–7.
- [9] Yang Stig, Qian Hoijun, Xia Yun, et al. Emergency ureteroscopic treatment for upper urinary tract calculi obstruction associated with acute renal failure: feasible or not? *J Endourol* 2010;**24**(11):1721–4.
- [10] Jiang Haowen, Wu Zhong, Ding Qiang. Ureteroscopy and holmium: YAG laser lithotripsy as emergency treatment for acute renal failure caused by impacted ureteral calculi. *Urology* 2008;**72**:504–7.
- [11] Tang ZY, Ding J, Peng KL, et al. Holmium: YAG laser lithotripsy under ureteroscopy for treating urinary calculi combined with acute renal failure. *Zhong Nan Da Xue Xue Bao Yi Xue Ban (J Central South Univ Med Sci)* 2006;**31**(1):125–7.
- [12] Safwat Ahmed S, Bissada Nabil K, Kumar Udaya, et al. Ureteroscopic holmium laser lithotripsy in patients with renal impairment. *Int Urol Nephrol* 2008;**40**:15–7.
- [13] El-Hefnawy Ahmed S, El-Nahas Ahmed R, El-Tabey Nasr A, et al. Bilateral same-session ureteroscopy for treatment of ureteral calculi: critical analysis of risk factors. *Scand J Nephrol Urol* 2011;**45**(2):97–101.
- [14] Alapont JM, Broseta E, Oliver F, et al. Ureteral avulsion as a complication of ureteroscopy. *Int Braz J Urol* 2003;**29**(1):18–23.
- [15] Chow GK, Atterson DE, Blute ML, Segura JW. Ureteroscopy effect of technology and technique on clinical practice. *J Urol* 2003;**170**:99–102.
- [16] Srivastava A, Gupta R, Kumar A, Kapoor R, Mandhani A. Routine stenting after ureteroscopy for distal ureteral calculi is unnecessary: results of a randomized controlled trial. *J Endourol* 2003;**17**(10):871–4.
- [17] Jeong H, Hwak C, Lee SE. Ureteric stenting after ureteroscopy for ureteric stones: a prospective randomized study assessing symptoms and complications. *BJU Int* 2004;**93**:1032–5.
- [18] Desai MR, Patel SB, Desai MM, Kukreja R, Sabnis RB, Desai RM, et al. The Dretler stone cone: a device to prevent ureteral stone migration – the initial clinical experience. *J Urol* 2002;**167**:1985–8.
- [19] Han DJ, Moon HY, Kim CS. Efficacy of the NTrap for the treatment of ureteral stone: an initial clinical experience. *Korean J Urol* 2007;**48**:1161–4.