



Assessment of Right Ventricular Function by 2D Speckle Tracking Echocardiography Pre and Post the Trans Catheter Closure of Atrial Septal Defect

**Saad Abd Elmaseh Saad^{1*}, Mohamed Elsayed Elsetiha¹,
Mohamed Naseem Hussein¹ and Fatma Aboalsoud Taha¹**

¹Cardiovascular Medicine Department, Faculty of Medicine, Tanta University, Egypt.

Authors' contributions

This work was carried out in collaboration among all authors. All authors read and approved the final manuscript.

Article Information

DOI: 10.9734/JAMMR/2021/v33i1731034

Editor(s):

(1) Dr.Murali P.Vettath, MEITRA Hospital, India.

Reviewers:

(1) Georges Ghanem, Lebanese American University, Lebanon.

(2) Ali Sadeghpour Tabaei, Iran University of Medical Science, Iran.

Complete Peer review History: <https://www.sdiarticle4.com/review-history/70624>

Original Research Article

Received 20 May 2021
Accepted 24 July 2021
Published 02 August 2021

ABSTRACT

Background: dysfunction is associated with adverse outcomes in patients with congenital heart disease. RV adaptation to disease is complex and depends on many factors. 2D Speckle tracking echocardiography is an angle-independent technique that may allow an accurate assessment of segmental myocardial deformation.

Aims: The aim of the work is to assess right ventricular function in patients with congenital left to right shunt (ASD) pre and 3 month post device closure using.

Patients and Methods: 31 patients were enrolled in the study, comparison was held between the group and itself before and 3 month after device closure. ESPAP measurement via TR jet also Tricuspid annular. Global longitudinal Strain of RV free wall and septum were measured by 2D STE.

Results: Volume overload on RV and according to Frank Starling law leads to increased contractility provided that function is preserved, so volume load in ASD cases leads to increased deformation and deformation rate values as evidenced in significant reduction of strain and strain rate values after volume load elimination. Strain and strain rate values gained via 2D speckle tracking echocardiography are load dependent parameter of contractility as evidenced in this study

*Corresponding author: E-mail: dr.saadsad@gmail.com;

testing RV performance under both pressure and volume load. The value of these parameters of contractility assessment comes from their ability to detect subtle changes in mechanics and deformation that are not easily detected by conventional measures.

Conclusion: Myocardial deformation imaging is a novel echocardiographic tool for evaluation of global and regional myocardial function that can be applied to the RV for assessment of its longitudinal deformation by 2DE. 2D-STE derived strain and strain rate is a good method to exclude the effect of tethering and translational motions. RV responds to volume load by increasing its deformation and deformation rate provided that contractile function is preserved.

Keywords: Right ventricular function; 2D speckle tracking echocardiography; atrial septal defect.

1. INTRODUCTION

For decades, the right ventricle (RV) has been considered 'dispensable' for cardiac function and consequently ignored. The introduction of the Fontan procedure for complex congenital heart disease in 1968, a technique that directly connects the right atrium to the pulmonary artery, thus 'bypassing' the RV, cemented this belief. Only in the second half of the past century, after recognizing its key role in various physiological [1] and pathological conditions, [2–5] the RV regained attention.

The RV performance defines prognosis in patients with congenital heart disease [2]. In this population group, the RV may be subjected to either volume (atrial septal defect, pulmonary, and/or tricuspid regurgitation) or pressure overload (pulmonary stenosis, atrial switch operations, congenitally corrected transpositions).

Assessing RV morphology and function is of paramount importance in acquired diseases as well. The RV has a great impact on the prognosis of patients with pulmonary hypertension, myocardial infarction involving the RV, and left ventricular (LV) dysfunction [5,6].

Echocardiography, being non-invasive, widely available, relatively inexpensive, and having no side effects, is the modality of choice for the assessment of morphology and function of the RV in clinical practice. Recent developments have provided several new methods for analyzing the RV, each having advantages and disadvantages. Doppler myocardial imaging (DMI), speckle tracking, or 3D echocardiography (3D Echo) are some of the techniques that may now add to a better understanding of RV function.

2. PATIENT AND METHODS

This study was carried out in Tanta university hospital echocardiographic and catheterization

laboratories from March 2019 to October 2020 on 31 patients with congenital ASD. They were enrolled in the study after obtaining their written informed consent themselves or their parents, and approval of Ethics Committee of Tanta University.

2.1 Inclusion Criteria

- Patient with congenital ASD.
- Single shunt lesion patients (i.e exclusion of patients with combined lesions that alter haemodynamics).
- Signs of RV volume overload.
- Dilated RV
- Impaired RV function
- Tricuspid regurgitation
- Diastolic flattening of interventricular septum "D-shaped"
- Significant left to right shunt ($Q_p / Q_s > 2$).

2.2 Exclusion Criteria

- Inadequate atrial septal rims.
- Proximity of the defect to atrioventricular valves or coronary sinuses.
- Pulmonary vascular resistance greater than 6 woods.
- Other concomitant congenital heart disease.
- Other concomitant valvular heart disease.
- Other concomitant coronary artery disease.
- Arrhythmias.

2.3 All Selected Patients Undergone

- Full history taking:
- Full clinical examination both general and local:
- Twelve-lead surface ECG:
- Plain chest X-ray:
- Routine laboratory investigations:

2.4 Statistical Analysis

Statistical presentation and analysis of the present study was conducted,

using the mean, standard deviation and chi-square test by SPSS V.16.

3. RESULTS

Table 1. Comparison between the Echo parameters pre and 3 months post device implantation

ECHO	Pre	3 months	t	p
Conventional ESPAP				
Min. – Max.	20.0 – 35.0	15.0 – 29.0	15.451 [*]	<0.001 [*]
Mean ± SD.	27.55 ± 3.17	20.71 ± 3.24		
Decrease	6.84 ± 2.46			
LVEF				
Min. – Max.	65.0 – 82.0	66.0 – 82.0	3.451 [*]	0.002 [*]
Mean ± SD.	72.94 ± 4.64	74.74 ± 4.78		
Increase	1.81 ± 2.91			
TAPSE				
Min. – Max.	12.0 – 17.0	17.20 – 22.60	35.580 [*]	<0.001 [*]
Mean ± SD.	14.40 ± 1.54	19.72 ± 1.58		
Increase	5.32 ± 0.83			
RVEDD				
Min. – Max.	21.0 – 35.0	15.0 – 22.0	28.383 [*]	<0.001 [*]
Mean ± SD.	27.19 ± 2.83	18.46 ± 2.47		
Decrease	8.73 ± 1.71			

t: Paired t-test; p: p value for comparing between pre and 3 months; *: Statistically significant at p ≤ 0.05

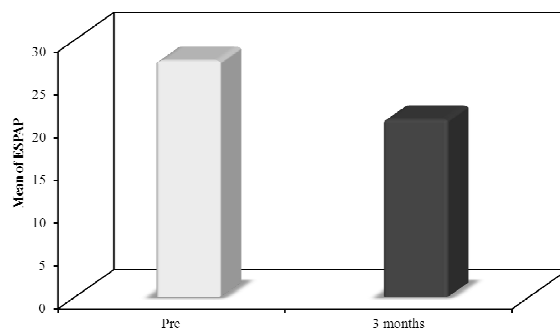


Fig. 1. Comparison between the ESPAP pre and 3 months post device implantation

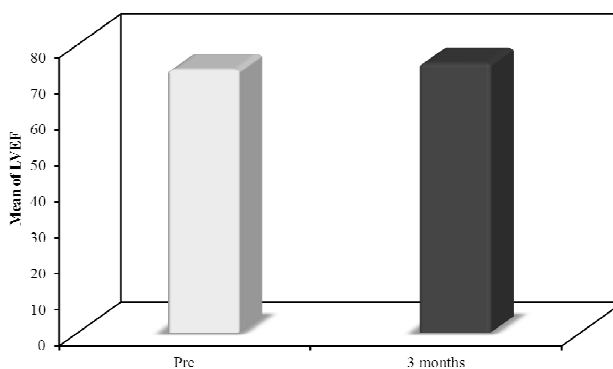


Fig. 2. Comparison between the LVEF pre and 3 months post device implantation

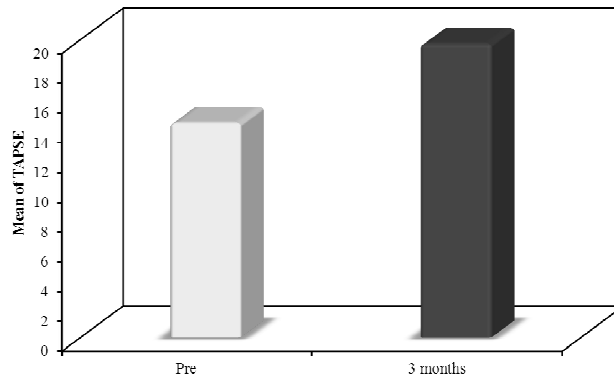


Fig. 3. Comparison between the TAPSE pre and 3 months post device implantation

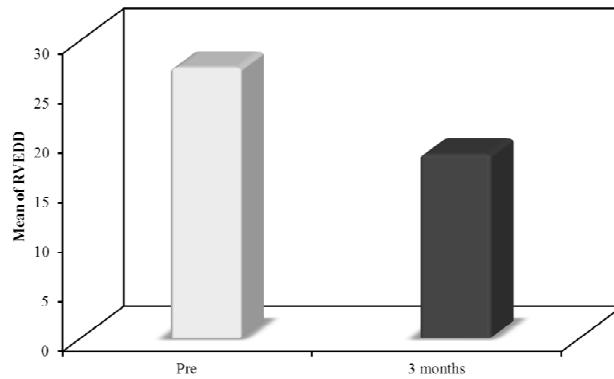


Fig. 4. Comparison between the RVEDD pre and 3 months post device implantation

Table 2. Comparison between global longitudinal strain (GLS) pre and 3 months post device implantation

GLS	Pre	3 months	t	p
Min. – Max.	17.50 – 21.50	22.10 – 26.90	35.580*	<0.001*
Mean ± SD.	-19.26 ± 1.12	-24.23 ± 1.40		
Increase	4.96 ± 1.27			

t: Paired t-test; p: p value for comparing between pre and 3 months; *: Statistically significant at $p \leq 0.05$

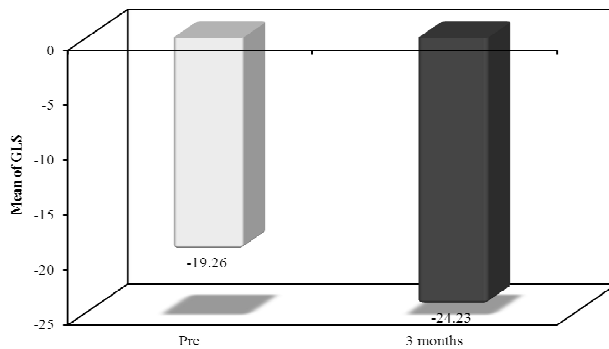


Fig. 5. Comparison between global longitudinal strain (GLS) pre and 3 months post device implantation

4. DISCUSSION AND CONCLUSION

The present study was designed to evaluate right ventricular function in a category of patients of congenital heart disease in whom RV function is of paramount importance regarding morbidity and mortality, those having congenital Lt to Rt shunt before and after transcatheter device closure of their shunts.

The present study demonstrated that the RV shows subtle adaptive changes of its mechanics in congenital heart defects associated with changes in its loading conditions whether volume or pressure load, which can be identified by 2D Speckle Tracking Echocardiography (2D STE). This technique permits the detection of early changes in RV function in different loading conditions.

RV afterload represents the load that the RV has to overcome during ejection. Compared with the LV, the RV demonstrates a heightened sensitivity to afterload changes [7,8]. Although in clinical practice, pulmonary vascular resistance (PVR) is the most commonly used index of afterload, PVR may not reflect the complex nature of ventricular afterload. A more complete model would ideally take into account the static and dynamic components of pulmonary vascular impedance as well as potential valvular or intracavitary resistive components [9].

RV preload represents the load present before contraction. Within physiological limits, an increase in RV preload improves myocardial contraction on the basis of the Frank-Starling mechanism. Beyond the physiological range, excessive RV volume loading can compress the LV and impair global ventricular function through the mechanism of ventricular interdependence [10]. Compared with LV filling, RV filling normally starts before and finishes after. RV isovolumic relaxation time is shorter, and RV filling velocities (E and A) and the E/A ratio are lower. The respiratory variations in RV filling velocities are, however, more pronounced [11,12]. Many factors influence RV filling, including intravascular volume status, ventricular relaxation, ventricular chamber compliance, heart rate, passive and active atrial characteristics, LV filling, and pericardial constraint [13]. The filling period is also an important determinant of ventricular preload and function.

Reduced RV deformation is not synonymous with myocardial injury in the context of marked

changes in afterload, this concept was the basis of the study design by Simon et al. [14], in which controls were compared with two groups of patients with pulmonary hypertension, those with or without RV failure as defined by elevated right atrial pressures on cardiac catheterization. RV free wall strain decreased progressively from controls to those with elevated pulmonary pressures and then further to those with concomitant RV failure.

In the present study and as goes with Frank-Starling law, increase in preload within limits (i.e. to the limit not inducing myocardial dysfunction), improves contractility and thus deformation and deformation rate as evidenced in ASD cases in whom, values of strain and strain rate both global, segmental and cumulative RV free wall decreased significantly after ASD device closure returning to their normal values after eliminating volume load.

In our study which performed on 31 patients ASD (8.18 \pm 3.63 mean age) who presented with different complains as dyspnea, recurrent chest infection and low weight for age by conventional echocardiography and 2D speckle tracking echocardiography before and 3 months after percutaneous closure. There is no significant changes in LVEF before (72.94 \pm 4.64) and after (74.74 \pm 4.78).

On other hand there is significant changes in RVEDD which decreased markedly after closure (27.19 \pm 2.83 mm to 18.46 \pm 2.47 mm, p<0.001).

Tricuspid annular plane systolic excursion (TAPSE) also affected which increased after closure (14.40 \pm 1.54 mm to 19.72 \pm 1.58mm, p < 0.001).

There is significant decrease in end systolic pulmonary artery pressure (ESPA) after closure (27.55 \pm 3.17mmhg to 20.71 \pm 3.24mmhg, p <0.001).

There is a statistically significant difference between global longitudinal strain (GLS) pre and 3 months post device implantation (-19.26 \pm 1.12 to -24.23 \pm 1.40, p <0.001).

5. RECOMMENDATIONS

The present study recommends:

- Future studies dealing with a large number of patients are needed to verify the above

results and to throw more light onto this important issue.

- It is better that, patients should be homogenized according to age and shunt fraction.
- 2D-STE should be considered as an essential part of routine echocardiography in congenital heart disease patients to verify subtle changes in contractility and function of RV that proved association with morbidity and mortality of these patients.
- More effort should be exerted in the near future to solve the technical problems and pitfalls of the strain and strain rate imaging.

CONSENT AND ETHICAL APPROVAL

They were enrolled in the study after obtaining their written informed consent themselves or their parents, and approval of Ethics Committee of Tanta University.

COMPETING INTERESTS

Authors have declared that no competing interests exist.

REFERENCES

1. LaGerche A, Connelly KA, Mooney DJ, MacIsaac AI, Prior DL. Biochemical and functional abnormalities of left and right ventricular function after ultra-endurance exercise. *Heart*. 2008;94:860-6.
2. Davlouros PA, Niwa K, Webb G, Gatzoulis MA. The right ventricle in congenital heart disease. *Heart*. 2006;92:i27-i38.
3. Voelkel NF, Quaife RA, Leinwand LA, Barst RJ, McGoon MD, Meldrum DR, Dupuis J, Long CS, Rubin LJ, Smart FW, Gladwin M, Denholm EM, Gail DB. Right ventricular function and failure: Report of a National Heart, Lung, and Blood Institute Working Group on Cellular and Molecular Mechanisms of Right Heart Failure. *Circulation*. 2006;114:1883-91.
4. D'Alonzo GE, Barst RJ, Ayres SM, Bergofsky EH, Brundage BH, Detre KM. Survival in patients with primary pulmonary hypertension: results from a national prospective registry. *Ann Intern Med*. 1991;115:343-9.
5. Juilliere Y, Barbier G, Feldmann L, Grentzinger A, Danchin N and Cherrier F. Additional predictive value of both left and right ventricular ejection fractions on long-term survival in idiopathic dilated cardiomyopathy. *Eur Heart J*. 1997;18:276-80.
6. Chin KM, Kim NH, Rubin LJ. The right ventricle in pulmonary hypertension. *Coron Artery Dis*. 2005;16:13-8.
7. MacNee W. Pathophysiology of cor pulmonale in chronic obstructive pulmonary disease: Part one. *Am J Respir Crit Care Med*. 1994;150:833-852.
8. Chin KM, Kim NH and Rubin LJ. The right ventricle in pulmonary hypertension. *Coron Artery Dis*. 2005;16:13-18.
9. Dell'Italia LJ. The right ventricle: Anatomy, physiology, and clinical importance. *Curr Probl Cardiol*. 1991;16:653-720.
10. Bouali Y, Donal E. Ventricular Interdependence and Biventricular Failure: Key Concept for Heart Failure Management. *Romanian Journal of Cardiology* | Vol. 2021;31(2).
11. Yu CM, Sanderson JE, Chan S, Yeung L, Hung YT, Woo KS. Right ventricular diastolic dysfunction in heart failure. *Circulation*. 1996;93:1509-1514.
12. Burgess MI, Mogulkoc N, Bright-Thomas RJ, Bishop P, Egan JJ, Ray SG. Comparison of echocardiographic markers of right ventricular function in determining prognosis in chronic pulmonary disease. *J Am Soc Echocardiogr*. 2002;15:633-639.
13. Dell'Italia LJ. Mechanism of postextrasystolic potentiation in the right ventricle. *Am J Cardiol*. 1990;65:736-741.
14. Simon MA, Rajagopalan N, Mathier MA, Sanjeev G Shroff, Michael R Pinsky, Angel López-Candales. Tissue doppler imaging of right ventricular decompensation in pulmonary hypertension. *Congest Heart Failure*. 2009;15:271-276.

© 2021 Saad et al.; This is an Open Access article distributed under the terms of the Creative Commons Attribution License (<http://creativecommons.org/licenses/by/4.0>), which permits unrestricted use, distribution, and reproduction in any medium, provided the original work is properly cited.

Peer-review history:

The peer review history for this paper can be accessed here:
<https://www.sdiarticle4.com/review-history/70624>