



Parotid Abscess in an Ulcerative Colitis Patient on Infliximab: A Case Report

Nacer Sara ^{a*}, Haddad Fouad ^a,
El Rhaoussi Fatima-Zahra ^a, Tahiri Mohamed ^a,
Hliwa Wafaa ^a, Bellabah Ahmed ^a and Badre Wafaa ^a

^a Hepato-Gastro-Enterology Department, UHC Ibn Rochd, Casablanca, Morocco.

Authors' contributions

This work was carried out in collaboration among all authors. All authors read and approved the final manuscript.

Article Information

Open Peer Review History:

This journal follows the Advanced Open Peer Review policy. Identity of the Reviewers, Editor(s) and additional Reviewers, peer review comments, different versions of the manuscript, comments of the editors, etc are available here: <https://www.sdiarticle5.com/review-history/98371>

Case Study

Received: 01/02/2023

Accepted: 03/04/2023

Published: 11/04/2023

ABSTRACT

Anti-Tumor Necrosis Factor- alpha (anti-TNF α) is a widely used immunosuppressive drug in inflammatory bowel disease (IBD). Parotid abscess results as a complication of the primary parotitis. It is an uncommon condition, that occurs in immunocompromised host. To our knowledge, it seems to be the first case described in the literature of an ulcerative colitis who developed a parotid abscess as an adverse effect to infliximab.

Keywords: *Infliximab; Crohn's disease; parotid; abscess; antibody.*

1. INTRODUCTION

Anti-tumor necrosis factor alpha (anti-TNF α) is highly effective therapeutic tool in inflammatory bowel disease's (IBD) treatment [1]. However,

infections and malignancy are well recognized serious complications associated with this therapy [2]. The parotid gland is the largest and the most commonly affected salivary gland by inflammation [3]. We report an unusual case of

*Corresponding author: Email: saramedstudies@gmail.com;

parotid gland abscess that developed in an Ulcerative colitis (UC) patient while on anti-TNFalpha therapy.

2. CASE REPORT

A 16 year old female patient without significant past medical history was admitted to the hospital because of acute severe ulcerative colitis. High-dose intravenous methylprednisolone (50 mg IV) were ineffective. She was considered corticosteroid refractory. After screening for latent infections, a rescue biological therapy with infliximab was begun at the dose of 5 mg/kg with an excellent clinical response. Before the second infusion dose of infliximab, the patient presented with a history of painful, red and warm right sided facial swelling and fever (39°C). On examination, there was a 5×5 cm warm, tender, erythematous swelling overlying the right parotid gland which was mildly fluctuant and not discharging (Fig. 1).

Ultrasound of the parotid region revealed a hypoechoic lesion consistent with fluid collection posterior to the angle of the mandible (Fig. 2). Computed tomography (CT) scan of the neck revealed a hypodense nodular lesion of 44,7mmx 6,5 mm suggestive of parotid abscess with submandibular lymphadenitis measuring 8mm (Fig. 3).

The initial Blood tests found an elevated C-reactive protein CRP 177 mg/dL and neutrophilia 9850 / μ L. Pus was exuded from right Stensen's duct on compression of the gland externally yielding 3cc of purulent material. Bacterial cultures didn't identify any organism on gram stain and culture. The patient was treated with intravenous antibiotics (amoxicillin/ clavulanate) for 4 weeks then switched to oral antibiotic for 2 weeks. She achieved a total of 6 weeks antibiotic. After discharge, there was a noticeable clinical improvement, biological parameters normalized and abscess disappear on the ultrasound (Fig. 4).

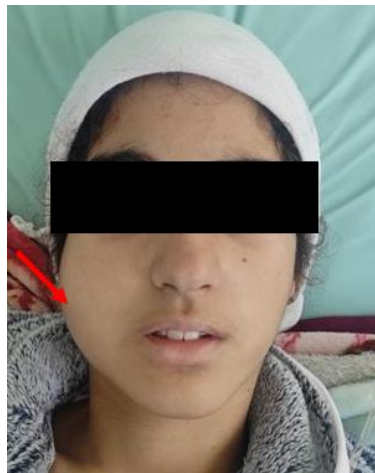

Fig. 1. Clinical picture showing tumefaction of the right parotid

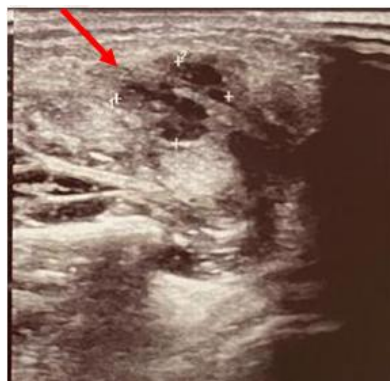

Fig. 2. Ultrasound image showing hypoechoic lesion of the right parotid gland with

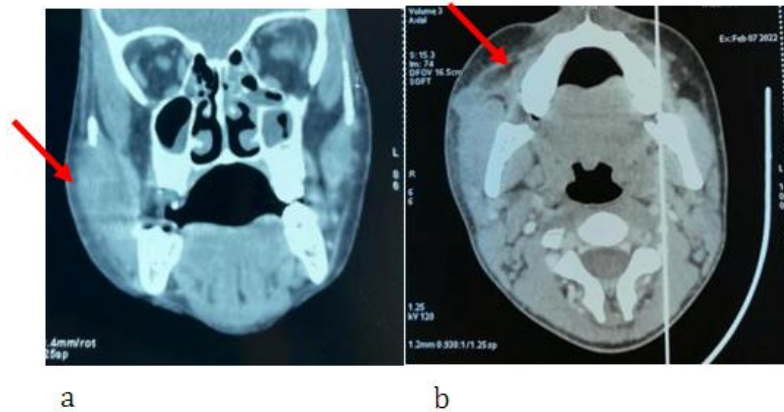


Fig. 3. CT scan head and neck with contrast at initial presentation
a) Coronal image
b) Axial image

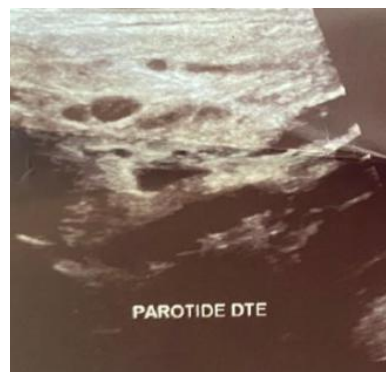


Fig. 4. Ultrasound image after the resolution of the parotid abscess

3. DISCUSSION

We present the first reported case of parotid gland abscess in a patient on infliximab therapy.

Infliximab is a chimeric anti-TNF monoclonal antibody who inhibit the TNF-alpha, a pro-inflammatory cytokine produced by macrophages and other inflammatory cells. It is used in the treatment of several immune-mediated inflammatory diseases such as IBD: Crohn's disease and Ulcerative colitis [1].

The literature supports an increased rate of infection with TNF- α inhibitors. Infliximab can be responsible of bacterial, fungal, viral and parasitic infections [2]. The parotid gland is a superficial salivary gland [3], most commonly infected by direct extension of microorganisms from the oral cavity via Stensen duct [4]. Other less common routes are hematogenous spread

and lymphatic spread from distant pulmonary focus. Predisposing factors of parotitis include ductal dysfunction, immunosuppression, dehydration, poor oral hygiene or dental infections [5]. In our case the patient was immunocompromised. The most frequently causative pathogen is *Staphylococcus aureus* [6]. However, low rate of positive culture of parotid abscess has been reported [7], as with our case

Clinical features include pain, warm, erythematous swelling and palpable mass in the preauricular region associated with marked fever and leukocytosis [8]. Our patient had presented this symptoms. The infection may be bilateral. On ultrasound, the parotid gland would be usually enlarged with oedema and increased vascularity and the collection would be seen as an hypoechoic lesion [9]. CT provide useful additional diagnostic imaging and permit to exclude possible underlying malignancy.

Management usually focuses on the use of intravenous empirical antibiotics guided thereafter by the culture results. Surgical drainage is indicated if failure of medical therapy or facial nerve involvement [8,10]. The prognosis of parotid abscess is good after adequate treatment. Fortunately, our patient did not develop facial nerve dysfunction and responded the treatment well without significant complication.

4. CONCLUSION

We report the first case of parotid gland abscess in a patient under anti-TNF.

Given the increasing incidence of IBD, the use of biologic therapies is expected to increase in the coming years. Thus, it is important to know the infectious risks associated with these drugs due to its immunosuppressive effects. So, a close follow-up is recommended.

CONSENT

As per international standard or university standard, parental(s) written consent has been collected and preserved by the author(s).

ETHICAL APPROVAL

As per international standard or university standard written ethical approval has been collected and preserved by the author(s).

COMPETING INTERESTS

Authors have declared that no competing interests exist.

REFERENCES

1. Hazeseleer C, Martiny D, Van Laethem Y, Cantinieaux B, Martin C. Reactivation of

- Plasmodium infection during a treatment with infliximab: A case report. *Int J Infect Dis.* 2020;91:101-103.
DOI: 10.1016/j.ijid.2019.11.016
2. Scheinfeld N. A comprehensive review and evaluation of the side effects of the tumor necrosis factor alpha blockers etanercept, infliximab and adalimumab. *J Dermatolog Treat.* 2004;15:280-94.
 3. Vorrasi J, Zinberg G. Concomitant suppurative parotitis and condylar osteomyelitis. *J Oral Maxillofac Surg.* 2017;75:543–549.
 4. Sikora AG, Rothstein SG, Garay KF, Spiegel R. Tuberculosis of the head and neck. In: Rom WN, Garay SM, editors. *Tuberculosis.* 2nd. Philadelphia, PA, USA: Lippincott Williams and Wilkins. 2004; 477–488.
 5. Viselner G, van der Byl G, Maira A, et al. Parotid abscess: mini-pictorial essay. *J Ultrasound* 2013;16:11–15.
 6. PampínOzán D, Cariati P, Arroyo Rodriguez S. Parotid abscess by *Candida glabrata*. *Med Clin (Barc).* 2021;156(10): 528.
DOI:10.1016/j.medcli.2020.01.017
 7. Ganesh R, Leese T. Parotid abscess in Singapore. *Singapore Med J.* 2005;46:553–6.
 8. Tan VE, Goh BS. Parotid abscess: a five-year review – clinical presentation, diagnosis and management. *J Laryngol Otol* 2007;121:872–879.
 9. Kolekar S, Chincholi TS, Kshirsagar A, Porwal N. Acute neonatal parotid abscess: A rare case report. *Afr J Paediatr Surg.* 2016;13(4):199-201.
DOI:10.4103/0189-6725.194675
 10. Lakshmi Narayana M, Azeem Mohiyuddin SM, Mohammadi K, et al. Parotid abscesses in children: A tertiary rural hospital experience. *Int J Pediatr Otorhinolaryngol.* 2015;79:1988–90.

© 2023 Sara et al.; This is an Open Access article distributed under the terms of the Creative Commons Attribution License (<http://creativecommons.org/licenses/by/4.0>), which permits unrestricted use, distribution, and reproduction in any medium, provided the original work is properly cited.

Peer-review history:
The peer review history for this paper can be accessed here:
<https://www.sdiarticle5.com/review-history/98371>