



Management of Isolated Post Traumatic Radial Head Dislocation in a Child: A Case Report

**S. Benzarti^{1*}, M. A. Triki¹, H. Kaziz¹, T. Mouelhi¹, M. L. Ben Ayeche¹
and N. Naouar¹**

¹*Department of Orthopedic Surgery and Trauma, Sahloul University Hospital, University of Sousse, Tunisia.*

Authors' contributions

This work was carried out in collaboration between all authors. All authors read and approved the final manuscript.

Article Information

DOI: 10.9734/AJPR/2018/v1i1124579

Editor(s):

(1) Dr. Emiliana Cristina Melo, Professor, Universidade Estadual do Norte do Parana, Campus Luiz Meneghel, Bandeirantes, Brazil.

Reviewers:

(1) N. S. Motsitsi, University of Pretoria, South Africa.

(2) Ali Al Kaissi, Orthopedic Hospital of Speising, Austria.

(3) Rafael Sanjuan-Cervero, Hospital de Denia, Spain.

Complete Peer review History: <http://www.sciencedomain.org/review-history/26061>

Case Study

Received 27th April 2018
Accepted 2nd July 2018
Published 31st August 2018

ABSTRACT

Post-traumatic dislocation of the radial head is a rare injury, generally described in the case of the Monteggia fracture associating a fracture of the ulnar diaphysis and a dislocation of the radial head. We report an exceptional case of an isolated post-traumatic dislocation in a 6-year-old child, who presented to our emergency department following a fall from a bike with a reception on the outstretched left arm.

Clinical examination showed a swollen left elbow painful to palpation with a limited and painful range of motion of the elbow especially pronation-supination. Plain radiographs of the left elbow and forearm showed an isolated anterior dislocation of the radial head.

Reduction was carefully performed followed by an above-the-elbow cast for 4 weeks with good functional and radiological outcome. Through this case report we insist on a systematic careful interpretation of plain radiographs of the elbow in children. With these precautions, diagnosis is not overlooked and an early management is initiated when the closed reduction is still possible.

*Corresponding author: E-mail: sofien.benzarti@yahoo.fr;

Keywords: Trauma; radial head; dislocation; elbow; child.

1. INTRODUCTION

Out of post-traumatic context, a radial head dislocation in children could be congenital, but a post-traumatic radial head dislocation in children is usually associated to a diaphyseal ulna fracture describing the well-known Monteggia fracture or associated to a plastic deformity of the ulna in some rare cases.

Post-traumatic isolated radial head dislocation is exceptional. Only a few cases have been reported in the literature.

Diagnosis is frequently delayed and plain radiographs are usually initially interpreted as normal.

2. CASE REPORT

We report the case of a 6-year-old female child who presented to our emergency department following a fall from her bike with a reception on her outstretched left arm.

Developmental history of the child was without any particularities; normal pregnancy, full-term baby without delivery difficulties, normal psychomotor development, no history of a

serious health condition, good school development and success without any emotional or behavioural problems.

Clinical examination showed a swollen left elbow painful to palpation without major deformity. The neuro-vascular study was normal. Range of motion of the elbow was limited and painful especially pronation-supination. The rest of the clinical examination was normal.

Plain radiographs of the left elbow and forearm showed an anterior dislocation of the radial head (A disrupted radio-capitellar line that should pass through the long axis of the radial neck and point towards the center of the capitellum). There was no radius or ulna fracture or plastic deformity (Fig. 1).

Reduction was carefully performed under analgesia using a gentle flexion and supination maneuver followed by an above-the-elbow cast for 4 weeks (Fig. 2). Control radiography showed a normal radial head positioning.

At 4 months of follow-up the patient was painless with a complete range of motion of the elbow. Plain radiographs show an intact radio-capitellar line (Fig. 3).

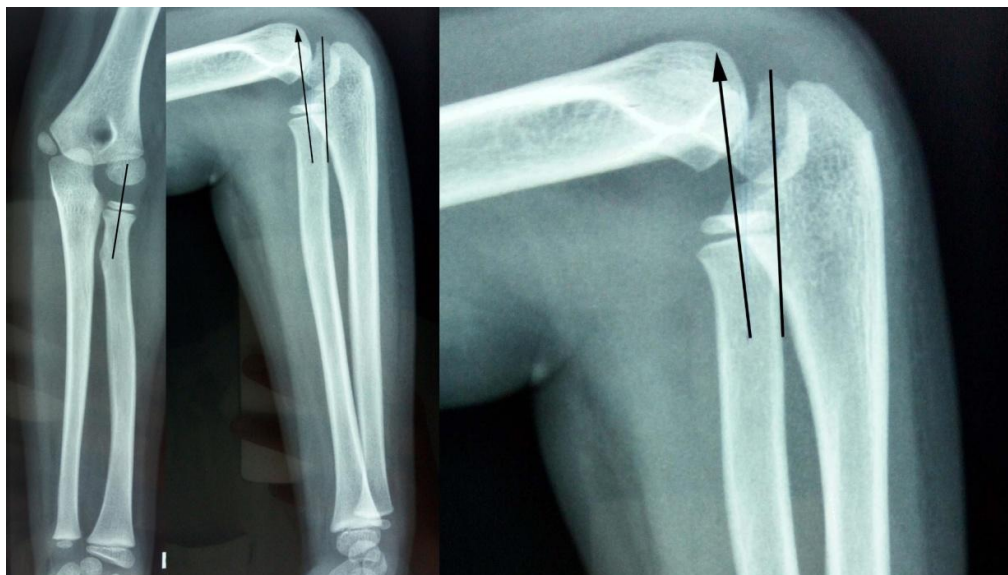


Fig. 1. Plain radiographs of the left elbow and forearm showed a disrupted radio-capitellar line (arrow-headed line). It should pass through the long axis of the radial neck and point towards the center of the capitellum (plain line). There was no radius or ulna fracture or plastic deformity

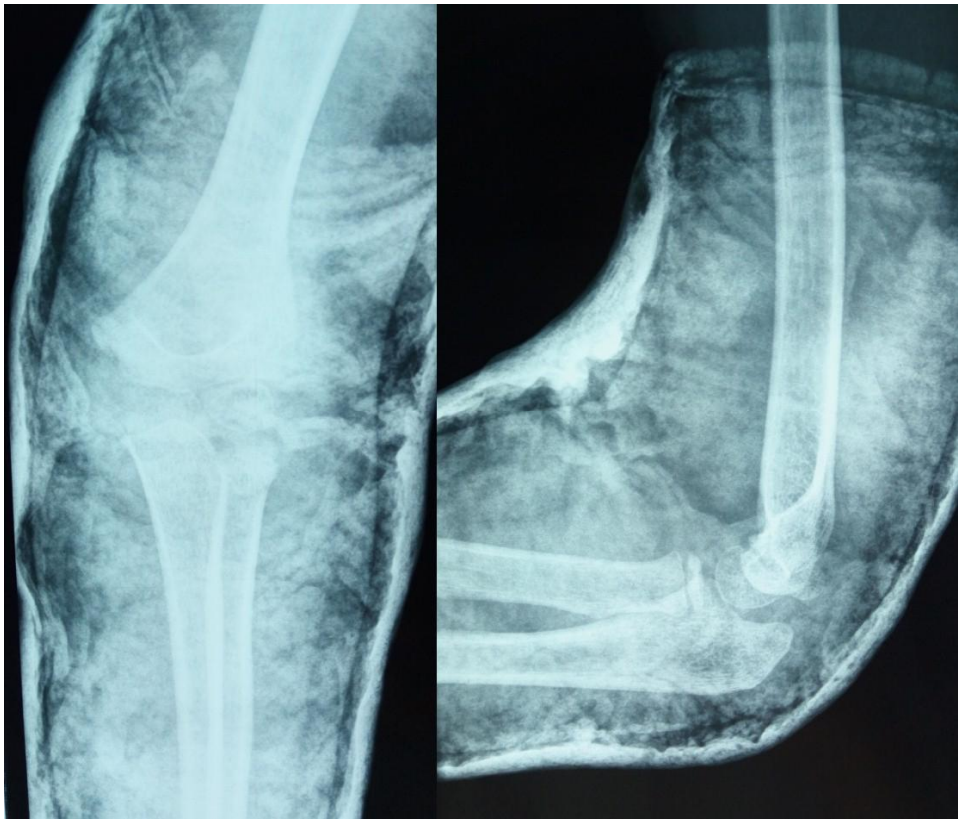


Fig. 2. Control radiography showed a normal radial head positioning in an above-the-elbow cast

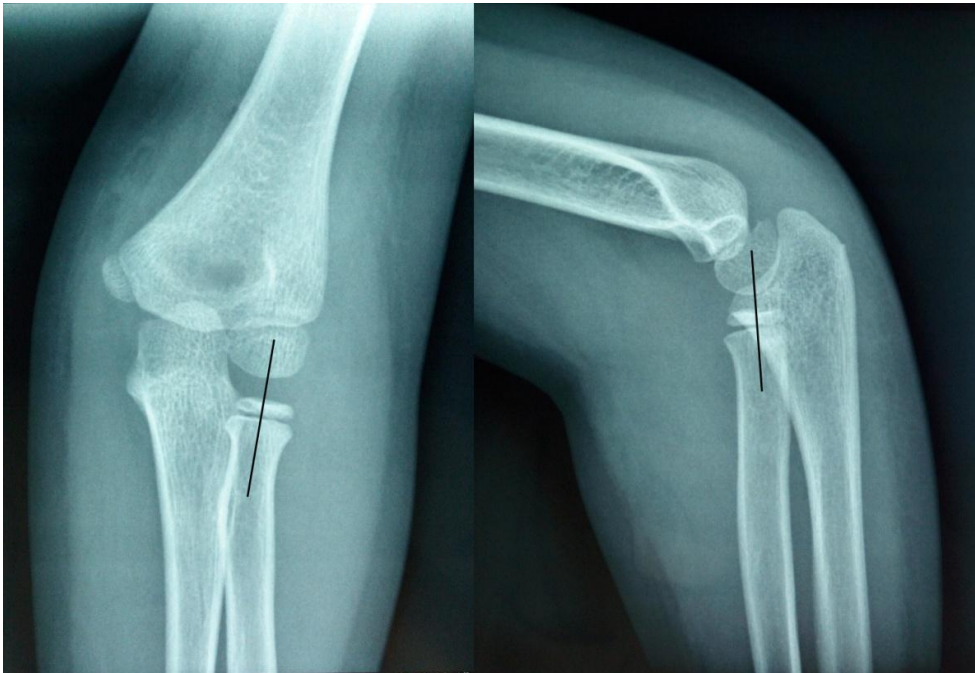


Fig. 3. Plain radiographs show an intact radio-capitellar line at 4 months of follow-up

3. DISCUSSION

Post-traumatic dislocation of the radial head is a rare injury, generally described in the case of the Monteggia fracture associating a fracture of the ulnar diaphysis and a dislocation of the radial head [1].

We report the case of an isolated post-traumatic dislocation in a child, which is an exceptional entity and only a few cases are reported in the literature [1–3].

It was mainly described as occurring after a trauma whose mechanism is difficult to specify, even if it is supposed to be an extension with varus of the elbow and pronation of the forearm. From an anatomopathological point of view, the trauma would be responsible for a rupture of the anterior or lateral annular ligament leading to the dislocation [2].

A recent biomechanical study demonstrated that the direction of radial head instability varied depending on the degree of soft tissue sectioning and specific forearm rotation and that anterior radial head dislocation may involve more severe ligament damage than other types of dislocation [3].

The clinical examination is not specific and finds the history of trauma, associated with a functional impairment of variable significance with or without a local edema. It eliminates a pulled elbow that occurs in the small child (up to the age of three years) for which the diagnosis is clinical (circumstances of occurrence, axial traction to children's upper extremity, the simple manual reduction is almost immediately efficient) [4].

Antero-posterior and lateral view of full forearm radiography, is essential for establishing the diagnosis. It makes it possible to objectify the presence of hemarthrosis, the integrity of the bony structures of the elbow joint (cortical rupture, epiphyseal separation, plastic deformation of the ulna) [5].

Plain radiographs show on the antero-posterior view an external or internal displacement of the radial head regarding the external condyle, and on the lateral view an anterior displacement in variable importance [1]. The antero-posterior view was apparently normal in our case, displacement of the radial head was only visible on the lateral view (Fig. 1).

The diagnosis is easily overlooked and the plain radiographs are frequently initially interpreted as normal. It is the persistence of the functional impairment with or without limitation of the range of motion [6] that leads the patient to return with a delay in diagnosis. When the dislocation persists for more than three months it becomes a chronic dislocation [2].

If no fracture is detected in the radiographs of a child presenting with a painful elbow and a limited range of motion, examining clinicians should look closely for a disrupted radiocapitellar line, indicating a radial head dislocation.

Surgical management is currently indicated in the case of chronic dislocations [6,7]. The most common technique is a reduction of the dislocation associated with a flexion osteotomy of the ulna and a reconstruction of the annular ligament [8,9]. The postoperative functional outcome is variable but seems to be related to the delay and the type of surgery.

4. CONCLUSION

Traumatic dislocation of the radial head is a rare injury. Only few cases have been reported in the literature. Its incidence seems to be underestimated and its diagnosis is frequently missed. Traumatic dislocation of the radial head should be suspected in case of a limitation of the pronation-supination of the elbow. Plain radiography confirms the diagnosis of dislocation.

When early diagnosed, closed reduction is still possible, followed by an immobilization in 90° of elbow flexion and neutral pronation-supination. If an open reduction is necessary, it allows the repair of the annular ligament.

CONSENT

As per international standard or university standard, the patient's written consent has been collected and preserved by the authors.

ETHICAL APPROVAL

As per international standard or university standard was written ethical approval has been collected and preserved by the authors.

COMPETING INTERESTS

Authors have declared that no competing interests exist.

REFERENCES

1. Wattincourt L, Seguin A, Seringe R. Lésions de Monteggia anciennes chez l'enfant A propos de 14 observations. In: Annales de Chirurgie de la Main et du Membre supérieur. Elsevier. 1999;137–148.
2. Seel MJ, Peterson HA. Management of chronic posttraumatic radial head dislocation in children. J Pediatr Orthop. 1999;19(3):306–312.
3. Hayami N, Omokawa S, Iida A, Kraisarin J, Moritomo H, Mahakkanukrauh P, et al. Biomechanical study of isolated radial head dislocation. BMC Musculoskelet Disord [Internet]. 2017;18(1).
4. Cates RA, Steinmann SP, Adams JE. Irreducible anteromedial radial head dislocation caused by the brachialis tendon: A case report. J Shoulder Elbow Surg. 2016;25(8):e232–5.
5. Bhangu A, Harun Y, Dias R. “No bony injury seen”: Radial head dislocation. Emerg Med J. 2009;26(3):222–222.
6. Freedman L, Luk K, Leong JC. Radial head reduction after a missed Monteggia fracture: Brief report. J Bone Joint Surg Br. 1988;70(5):846–847.
7. Kim HT, Conjares JNV, Suh JT, Yoo CI. Chronic radial head dislocation in children, Part 1: Pathologic changes preventing stable reduction and surgical correction. J Pediatr Orthop. 2002;22(5):583–590.
8. Boumpoutou R, Guérin B, Borocco A, Mouret G, Choulot JJ. Luxation post-traumatique isolée de la tête radiale chez un enfant. J Eur Urgences. 2004;17(2):79–82.
9. Wilkins KE. Changes in the management of Monteggia fractures. J Pediatr Orthop. 2002;22(4):548–554.

© 2018 Benzarti et al.; This is an Open Access article distributed under the terms of the Creative Commons Attribution License (<http://creativecommons.org/licenses/by/4.0>), which permits unrestricted use, distribution, and reproduction in any medium, provided the original work is properly cited.

Peer-review history:

The peer review history for this paper can be accessed here:
<http://www.sciencedomain.org/review-history/26061>