



Disorders of sexual development in a cultural context

Hüseyin Özbey & Seref Etker

To cite this article: Hüseyin Özbey & Seref Etker (2013) Disorders of sexual development in a cultural context, Arab Journal of Urology, 11:1, 33-39, DOI: [10.1016/j.aju.2012.12.003](https://doi.org/10.1016/j.aju.2012.12.003)

To link to this article: <https://doi.org/10.1016/j.aju.2012.12.003>



© 2013 Arab Association of Urology



Published online: 05 Apr 2019.



Submit your article to this journal [↗](#)



Article views: 540




View related articles [↗](#)



Arab Journal of Urology
(Official Journal of the Arab Association of Urology)

www.sciencedirect.com



PEDIATRIC UROLOGY

REVIEW

**Disorders of sexual development
in a cultural context**

Hüseyin Özbey^{a,b,*}, Seref Etker^b

^a Department of Pediatric Surgery, Division of Pediatric Urology, Istanbul University, Istanbul Medical Faculty, Çapa, Istanbul, Turkey

^b DSDturk – Association of Disorders of Sex Development and Hypospadias, Istanbul, Turkey

Received 15 September 2012, Received in revised form 9 December 2012, Accepted 13 December 2012

Available online 26 January 2013

KEYWORDS

Disorders;
Sexual development;
Gender assignment;
Culture;
Ethnicity

ABBREVIATIONS

(f-)CAH, (female)
congenital adrenal
hyperplasia;
(C)AIS, (complete)
androgen-insensitivity
syndrome; DSD,

Abstract Background: Disorders of sexual development (DSD) are congenital conditions in which the development of the chromosomal, gonadal or anatomical sex can be deemed atypical. The external genitalia should appear 'normal' in size and shape from birth, with no question of abnormality, and the individual must receive appropriate social-environmental feedback in the course of the sexual maturation process.

Methods: We review regional differences in the variables considered important for gender assignment in individuals with DSD. Various approaches to certain forms of DSD are analysed within their cultural context.

Results: The decision to leave the sex of rearing undisturbed or to change it is difficult. It depends on the patient's age and the extent to which the gender identity has been established with parental gender preference, social, cultural and religious factors. Severe forms of genetically female congenital adrenal hyperplasia, androgen insensitivity syndrome, 17 β -hydroxysteroid dehydrogenase-3, 5 α -reductase and cytochrome P450 oxidoreductase deficiencies are found to be the most difficult cases to diagnose and/or manage.

* Corresponding author. Address: Department of Paediatric Surgery, Division of Paediatric Urology, Istanbul University, Istanbul Medical Faculty, TR-34390 Çapa, Istanbul, Turkey. Tel.: +90 532540 37 20.

E-mail address: hozbey@istanbul.edu.tr (H. Özbey).

Peer review under responsibility of the Arab Association of Urology.



Production and hosting by Elsevier

disorder(s) of sexual development; 5-AR, 5 α -reductase; POR, cytochrome P450 oxidoreductase; 17BHSD-3, 17 β -hydroxysteroid dehydrogenase-3; TEOAE, transient evoked otoacoustic emissions

Conclusion: Gender assignment in children with DSD is a subject of intense debate. Each case of DSD must be evaluated individually and on its merits and potentials. Although early admission and appropriate diagnostic facilities could provide the correct diagnosis, this is not the case in some cultures. It is seen that 'gender panic', social and religious concepts affect the decision-making process in gender assignment, especially in delayed cases.

© 2013 Arab Association of Urology. Production and hosting by Elsevier B.V. All rights reserved.

Introduction

Disorders of sexual development (DSD) pose a unique challenge, both diagnostically and in terms of acute and longer-term management [1,2]. The wide spectrum of the clinical presentation of DSD is another aspect, and the interval of detection from the antenatal period into childhood or adolescence is also a factor to consider. Social, cultural and economic variables can also influence the attitudes of the parents for gender preference of a newborn or child with DSD. In any case, the situation is a difficult and stressful experience for both parents and the healthcare professionals, especially if there is a discordance between the genetic, gonadal and phenotypic sexual characteristics, and expectations [3].

There are variations in the management of DSD, not only between different continents and cultures, but also within countries, and to a certain extent among centres in the same country [4–6]. In this review we describe our experience and detail the various approaches to certain forms of DSD, within the cultural context.

Initial diagnosis and disclosure of information

It is now generally agreed that all children born with ambiguous external genitalia should be assigned a social gender as soon as possible, supported by the initial laboratory findings. However, these laboratory findings might only reveal the major pieces of a puzzling picture. Controversies on the evaluation of the final picture might occur between the families and the related healthcare providers, and even among the medical professionals. Also, the surgical treatment of an infant or child with DSD is highly controversial, as the consent of the person affected cannot be obtained directly.

The initial diagnosis of DSD must be made by a multidisciplinary team, where present, composed of a paediatric endocrinologist, geneticist, paediatric surgeon or urologist, and paediatric psychologist. The timing of the disclosure of information to the patient is mostly adapted to the child's maturity and the social characteristics of the family. Information about the medical and surgical condition must be disclosed appropriately, to conform with the parents' intellectual and social status.

The variables involved in the decision of sex assignment are determined by the culture, social characteristics and religious beliefs. Hence, the communication with families must be provided by a well-experienced person among those designated professionals.

DSD and gender assignment

DSD is classified as 46,XX (masculinisation of a female), 46,XY (undermasculinisation of a male), ovotesticular, 46,XX testicular (XX sex reversal), and 46,XY complete gonadal dysgenesis (XY sex reversal). Congenital adrenal hyperplasia (CAH) is the most common condition in newborns with DSD, accounting for 60–70% of all cases [3]. Abnormal steroidogenesis starts early in foetal development and presents as virilised external genitalia at birth, varying from mild clitoral hypertrophy to variable degrees of labial fusion. Sometimes complete labial fusion, a phallic urethra, and external meatus at the tip of the penis can be found, and the baby might be raised as male (Fig. 1). An intact fertility potential is maintained in the presence of a uterus, Fallopian tubes and ovaries. As a rule, a biologically female infant with CAH is preferably constructed anatomically and functionally. Thus, gender assignment in female CAH should not be controversial when diagnosed early, and appropriate medical and surgical experience is available [7]. A one-stage clitorovaginoplasty is the treatment of choice and can be completed in the neonate [8]. However, clitoral atrophy, abnormal sensation in the clitoris, and prominent glans clitoris have been reported as disappointing results [9,10].

Later gender changes in patients with female CAH (f-CAH) can lead to profound disturbances in gender identification, but it might also lead to good acceptance of the female gender role in adulthood [9,11]. Thus, the decision of gender reassignment is usually difficult, and depends largely on the age of the patient and to what extent the gender identity has been established (Fig. 2).

The most common cause of 46,XY DSD with a female phenotype is complete androgen-insensitivity syndrome (CAIS), the diagnosis of which currently relies on molecular biology. It is often identified at puberty because of

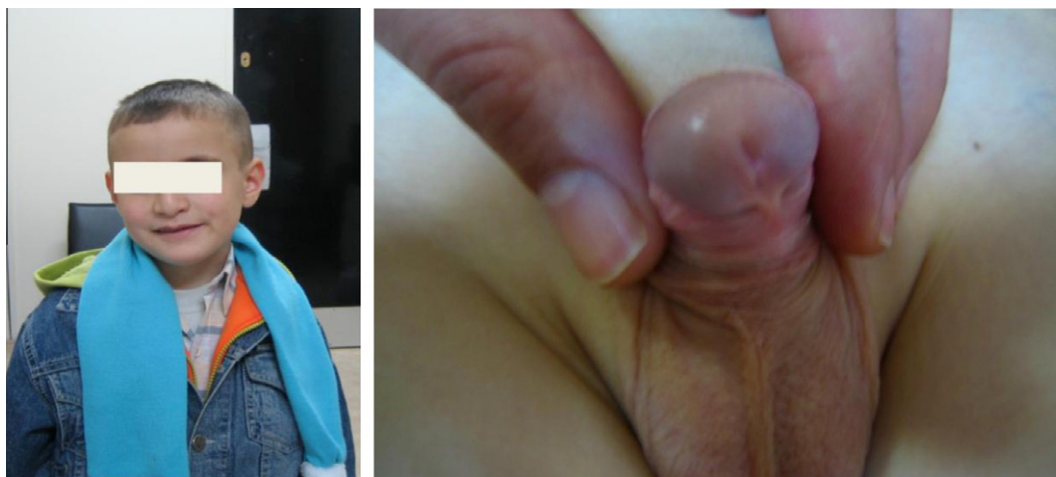


Figure 1 A 5-year-old patient with CAH (46,XX).

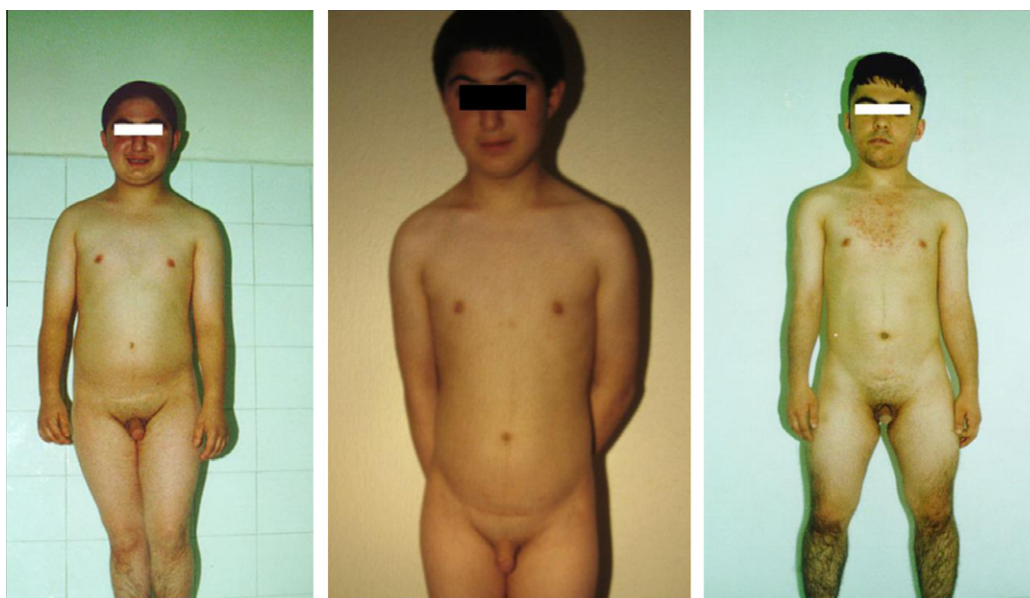


Figure 2 Patients with 46,XX CAH, reared as 'male'.

primary amenorrhoea associated with normal breast development and low or absent pubic and axillary hair. Its presentation can also be with bilateral inguinal hernias during childhood [12]. These individuals are born appearing externally as female, and uniformly raised as females; they are generally satisfied with their female gender and sexual function [13]. This might show the effect of androgen unresponsiveness of the brain, in addition to unambiguous female sex of rearing.

The association of the 46,XY karyotype with a female phenotype is not always synonymous with CAIS, as it can be due to several other factors, such as 17 β -hydroxysteroid dehydrogenase-3 (17BHSD-3) and 5 α -reductase (5-AR) deficiency. 17BHSD-3 deficiency is a rare, autosomal recessive cause of 46,XY DSD, but is frequently misdiagnosed as CAIS [14]. A national

cooperative study from the Netherlands showed that 67% of patients with 17BHSD-3 deficiency were misdiagnosed as having CAIS [15]. 17BHSD-3 deficiency is usually rare, but is common in populations with a high intermarriage rate, such as in the Arab population of Gaza [16,17]. Patients with 17BHSD-3 deficiency can be unnoticed at birth and raised as female, as female external genitalia (with a blind-ending vagina) are common. A newborn or a young girl with remarkable clitoromegaly, with or without an inguinal hernia, should raise suspicion. At puberty, clitoromegaly, as penile size with chordee, primary amenorrhoea, virilisation, and increased body hair are the usual physical findings (Fig. 3). To delay the intervention is not always feasible in 17BHSD-3 deficiency. A child with this deficiency who is severely undervirilised and has assumed a female

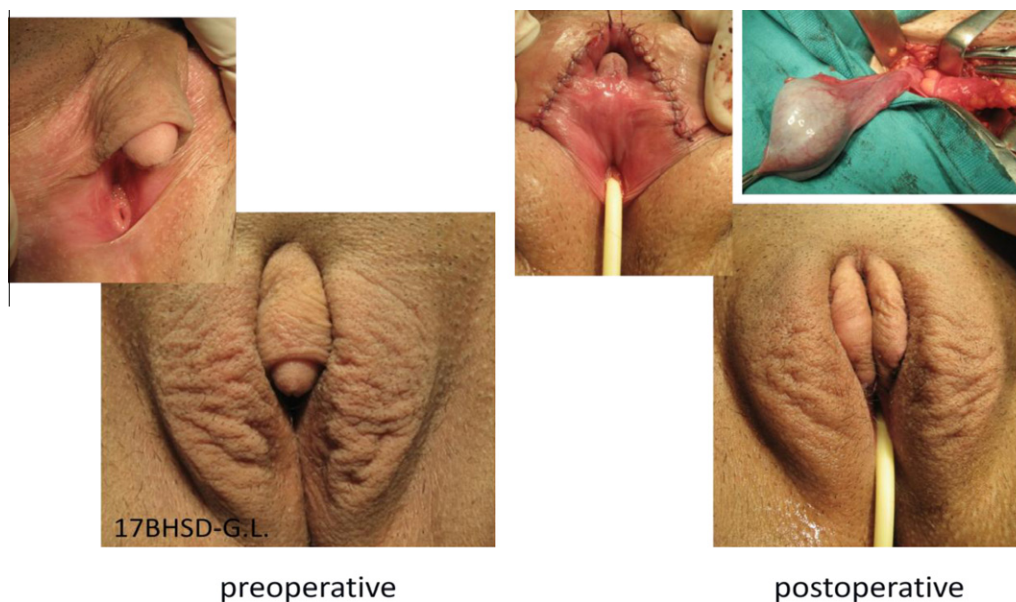


Figure 3 A 16-year-old patient with 17-BHSD-3 deficiency reared as a girl (before and after surgery).

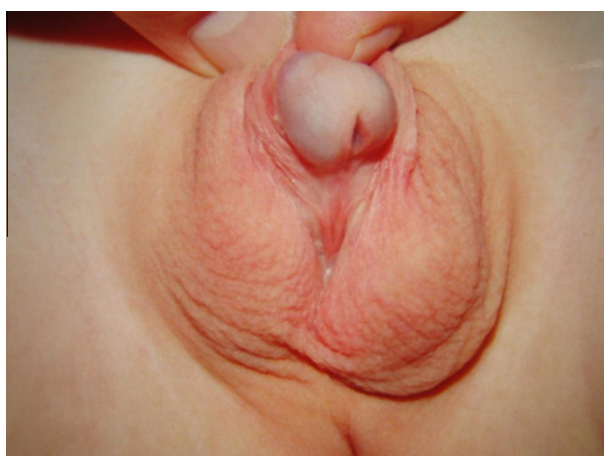

Figure 4 The external genital appearance of a patient with 5-AR deficiency.

gender role and identity, when left without gonadectomy, can undergo virilisation throughout childhood, especially at the onset of puberty. Also, early removal of the testes is recommended, because of the high rate of germ-cell malignancy (28%) [18]. However, with the help of testosterone treatment and corrective surgery, individuals raised as males can show satisfactory male development. Thus, the decision in either direction is still controversial, and there should be a prompt and accurate diagnosis with molecular genetic tests.

5-AR deficiency is another example of 46,XY DSD, in which patients are born with female-appearing external genitalia and raised as girls (Fig. 4). Pubertal virilisation occurs secondary to the increased production of other isoenzymes, allowing the conversion of testosterone to dihydrotestosterone. Exposure of the brain to

testosterone *in utero* and postnatally appears to contribute substantially to the formation of male-gender identity, despite the effect of a female sex of rearing.

Cytochrome P450 oxidoreductase (POR) deficiency is another (recently discovered) new variant of CAH [19]. POR deficiency can cause a DSD manifested as genital undervirilisation in 46,XY newborns, as well as overvirilisation in those who are 46,XX. The POR deficiency causes decreased production of androgens, resulting in severe male undervirilisation. Although challenging, appropriate surgical treatment should be used in patients with POR deficiency, allowing for the correct gender assignment (Fig. 5).

DSD and cultural and socio-economic effects

Attitudes towards the sex of rearing in early and late-diagnosed patients with DSD in Eastern societies are different from those in Europe. In certain communities where the male has a dominant role in financial and social life, there are strong social pressures, influenced by cultural, traditional and economic factors. Where the man is the traditional breadwinner, having a dominant role in institutional and social life, and the woman is the housewife and mother, a parental preference for the male gender is as, if not more, important than the individual's sexual potential [5,20–22]. To care for parents or to inherit family property, a male offspring is the common preference in the Turkish population, which sometimes results in consanguineous marriages. The parental consanguinity rate among Turkish families of patients with CAH is higher than in the general population in Turkey (56% vs. 21%) [23,24]. Among patients with f-CAH who were considered to be male before the diagnosis, significantly many of them had to

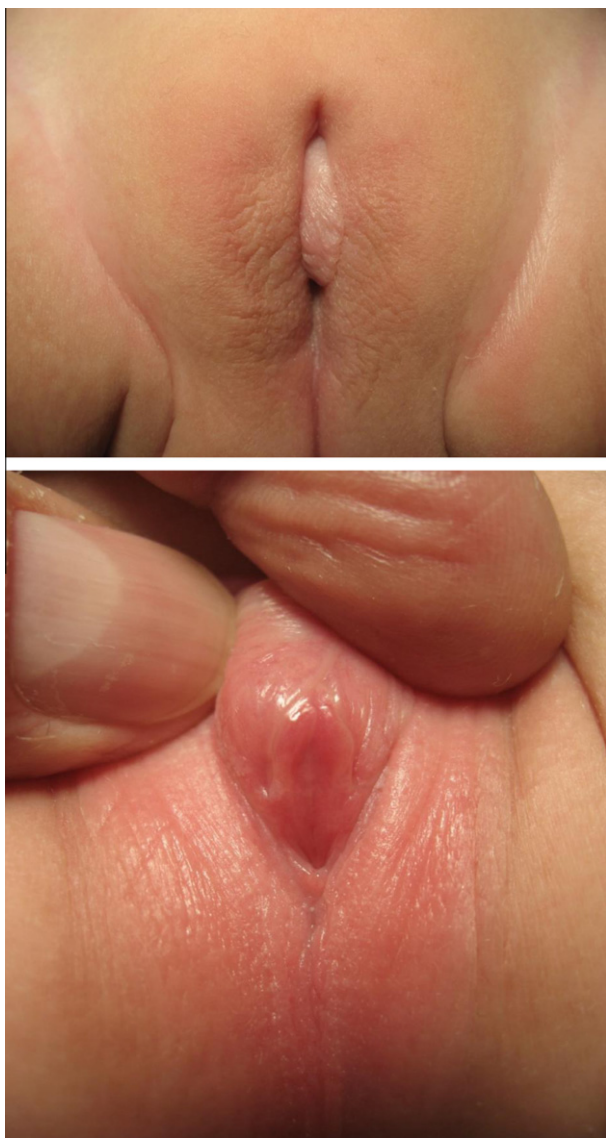

Figure 5 The external genital appearance of a 46,XY patient with POR deficiency.

be assigned as ‘male’, because of the development of a male gender identity at diagnosis [5,24]. In our study, 49 of 70 patients with f-CAH were reared as female and 21 as ‘male’. Only nine of these ‘males’ could be reassigned as females (mean age at presentation, 7.87 months). Twelve children had to be reared as ‘male’ (mean age at presentation, 55.8 months) in compliance with the parents’ and the study group’s decision, and appropriate masculinising reconstructive surgery was undertaken. The difference in the mean age of those reassigned as female and those who remained ‘male’ was significant ($P < 0.001$). The parental consanguinity rate among the families was especially high in the ‘male’ patients, reflecting the influence of the extended family and social factors on the preference for a male gender. In children who were raised as ‘male’, the decision was strongly influenced by the fear of social stigmatisation.

Discussion

DSD are congenital conditions in which the development of chromosomal, gonadal or anatomical sex is atypical or ambiguous [18]. Depending on the geographical, religious and cultural background, one in 300–4500 infants is born with abnormalities of the external genitalia. In the newborn period, virilisation or over-virilisation of the external genitalia in girls, and under-virilisation in boys, presenting as micropenis, hypospadias and undescended testes, are the most common presentations. However, there are more complex situations in which the determination of rearing might not be possible. In such cases, gonadal structure and the anatomy of the internal genitalia should also be considered, and an appropriate laboratory delineation is required. These disorders are now classified into three major categories: sex chromosome DSD, 46,XX DSD and 46,XY DSD. The DSD abbreviation can also be defined as ‘differences’ in sexual development, rather than disorders, with wide variations of the sexual characteristics from ‘statistically normal’.

The most characteristic differences in human behaviour are gender identity and sexual orientation, that are deeply affected by the external genital structure [25]. Both issues are closely related to certain criteria of anatomical and psychosexual development; the external genitalia should look ‘normal’ in size and shape, with no question of abnormality, and the individual must receive appropriate social and environmental influences. The most characteristic gender difference of the human body remains the external genitalia. Variation of the external genitalia from ‘the normal’ is not always the result of established DSD conditions. Mutations, deletions of the genes on sex-determining areas of sex chromosomes, and on the autosomes, and enzyme deficiencies are the most common causes of DSD, showing differences among populations and locations. However, in about half of the cases of DSD the molecular genetic diagnosis is unknown and the diagnosis rests on clinical features.

Animal studies showed that the ultimate feature of sexual behaviour in humans is a function of circulating sex hormones, particularly androgens, during a critical period before or immediately after birth. Such studies also indicated that the effects of early hormone exposure are expressed as changes in the ventral nervous system at the structural and functional levels [26].

Most multidisciplinary treatment teams for DSD currently recommend a male sex of rearing in under-androgenised 46,XY males with ambiguous genitalia due to 5-AR deficiency, and 17BHSD-3 deficiency or partial AIS, because there is growing evidence for increased gender dysphoria and gender change in these conditions [10,27]. More than 60% of 5-AR-deficient patients and half of 17BHSD-3-deficient patients assigned as females

in infancy ultimately change their gender role at puberty, due to virilisation and associated problems [28].

Gender identity also means being recognised as either male or female. Children with DSD are likely to have been the subject of medical and parental confusion about their typical sex (as male or female). The fear of the ‘possibility of homosexuality’ by the parents of children born with ambiguous genitalia is known as ‘gender panic’. The development of gender-role behaviour (complementary self-image) is influenced by the effects of the sex hormonal milieu before and during birth in the sexual differentiation of the brain, and by environmental learning [7,29,30]. Although there is a considerable overlap between gender identity and gender role, the latter includes the appropriate socialisation of a person, including dressing, playing and his/her occupation. Besides gender panic, social and religious concepts affect the decision-making process in gender assignment. This effect is reportedly more pronounced in the East and the Subcontinent [31]. Various factors, including the age at diagnosis, surgery and the potential for intercourse, fertility and gender adjustment, and available psychological support, affect the gender assignment of a patient with DSD. This makes the appearance of a phallus (both in size and palpable corporal/erectile tissue) a guiding principle. Micropenis can occur as part of a major defect in DSD and the question of the sex for rearing might arise. Not only penile agenesis, but a small phallus can dictate a female gender assignment at some stage [32,33]. The ‘potential for the phallus to function adequately in later sexual relations’ and ‘it is easier to construct a vagina than a satisfactory penis’ are simplistic approaches. Furthermore, it is supposed that the organ that appears to be critical to psychosexual development and adaptation is not solely the external genitalia [30]. The sexual dimorphism of the brain was first described in 1971 [34]. However, the effects of the prenatal endocrine milieu on the development of sexually dimorphic human brain is a novel field of research, and is much more complicated than the physical-sexual differentiation of the external genitalia [35,36]. In children with DSD, androgen imprinting must also be considered for the sex assignment, if not limited by anatomy.

Transient evoked otoacoustic emissions (TEOAE) are low-intensity, acoustic energy (sounds) produced by the cochlea and recorded in the ear canal as a result of brief acoustic stimulation. It is supposed that gender differences in TEOAEs depend on the amount of androgen exposure. Hence, we have obtained TEOAEs from eight genotypic female patients with f-CAH (all reared as ‘male’), six with mixed gonadal dysgenesis (MGD, four reared as male and two as female), and five with AIS (all reared as male). TEOAE levels from 20 healthy children were used as normal data. The patients’ psychosocial and gender adaptation, self-image and intellectual level were assessed by a semi-structured

Table 1 TEOAE results in children with DSD.

Group (n)	Mean (SD) TEOAE level (dB)
Controls (20)	
Male, 46,XY	21.9 (5.35)
Female, 46,XX	37.6 (6.87)
<i>P</i>	≤0.001
CAH, 46,XX (8)	21.2 (10.06)
<i>P</i>	< 0.001
MGD, 45,XO/46,XY (6)	29.5 (7.76)
CAIS, 46,XY (5)	36.1 (17.51)
<i>P</i>	< 0.001

interview and a questionnaire. It is shown that healthy female children had a significantly more sensitive (higher) mean (SD) TEOAE level than males. Highly virilised patients with f-CAH had significantly lower TEOAE levels than normal females, patients with AIS had higher TEOAE levels than normal males, patients with MGD had TEOAE levels between males and females (Table 1). All patients showed a discordance between TEOAEs and the genotypic features. Two patients (one each with f-CAH and AIS) showed gender-role behaviour of the opposite gender. These findings strongly support the view that gender differences on the TEOAE test are androgen-dependent [37]. Thus, TEOAEs might be useful in evaluating prenatal exposure to androgens and its possible masculinising effects on brain structures responsible for sexual orientation and sexual identity.

In recent years, DSD societies and support groups, mostly based in Western countries, have provided information about their experiences through the Internet [10,38,39]. Specialised centres are becoming accessible through networks, supporting the collection of data, providing practical advice, and evidence for optimal clinical and psychosocial management. Undoubtedly this is the single most significant development for the understanding and management of DSD in the future. Without a sound reference point, the misgivings in diagnosis, small sample sizes of DSD, limited funding for rarer diseases, lack of experienced independent care-providers and researchers, will prevent high-quality services. Hence, the management of DSD is still in many ways empirical and influenced by the microcosm of local factors at play.

Source of funding

None.

Conflict of interest

There is no conflict of interest.

References

- [1] Coran AG, Polley TZ. Surgical management of ambiguous genitalia in the infant and child. *J Pediatr Surg* 1991;**26**:812–20.
- [2] Reiner WG. Case study: sex reassignment in a teenage girl. *J Am Acad Child Adolesc Psychiatry* 1996;**35**:799–803.

- [3] Izquierdo G, Glassberg KI. Gender assignment and gender identity in patients with ambiguous genitalia. *Urology* 1993;**42**:232–42.
- [4] Josso N, Audi L, Shaw G. Regional variations in the management of testicular or ovotesticular disorders of sex development. *Sex Dev* 2011;**225**–34.
- [5] Özbey H, Darendeliler F, Kayserili H, Korkmazlar Ü, Salman T. Gender experience in female congenital adrenal hyperplasia: a difficult experience. *BJU Int* 2004;**94**:388–91.
- [6] Al-Maghribi H. Congenital adrenal hyperplasia. Problems with developmental anomalies of the external genitalia and sex assignment. *Saudi Kidney Dis Transpl* 2007;**18**:405–13.
- [7] Meyer-Bahlburg HF. Gender and sexuality in classic congenital adrenal hyperplasia. *Endocrinol Metab Clin North Am* 2001;**30**:155–71.
- [8] De Jong TPVM, Boemers TML. Neonatal management of female intersex by clitorovaginoplasty. *Urology* 1995;**154**:830–2.
- [9] Kuhnle U, Bullinger M. Outcome of congenital adrenal hyperplasia. *Pediatr Surg Int* 1997;**12**:511–5.
- [10] Köhler B, Kleinemeier E, Lux A, Hiort O, Grüters A, Thyen U, et al. Satisfaction with genital surgery and sexual life of adults with disorders of sex development: results from the German clinical evaluation study. *J Clin Endocrinol Metab* 1997;**2**:577–88.
- [11] Hurtig AL, Radhakrishnan J, Reyes HM, Rosenthal IM. Psychological evaluation of treated females with virilizing congenital adrenal hyperplasia. *J Pediatr Surg* 1983;**18**:887–93.
- [12] Cheikhelard A, Morel Y, Thibaud E, Lortat-Jacob S, Jaubert F, Polak M, et al. Long-term followup and comparison between genotype and phenotype in 29 cases of complete androgen insensitivity syndrome. *J Urol* 2008;**180**:1496–501.
- [13] Wisniewski AB, Migeon C. Long-term perspectives for 46,XY patients affected by complete androgen insensitivity syndrome or congenital micropenis. *Semin Reprod Med* 2002;**20**:297–304.
- [14] Alikasifoglu A, Hiort O, Gonc N, Demirbilek H, Isik E, Kandemir N. 17beta-hydroxysteroid dehydrogenase type 3 deficiency as a result of a homozygous 7 base pair deletion in 17betaHSD3 gene. *J Pediatr Endocrinol Metab* 2012;**25**:561–3.
- [15] Boehmer AL, Brinkmann AO, Sandkuijl LA, Halley DJ, Niermeijer MF, Andersson S, et al. 17Beta-hydroxysteroid dehydrogenase-3 deficiency, diagnosis, phenotypic variability, population genetics, and worldwide distribution of ancient and de novo mutations. *J Clin Endocrinol Metab* 1999;**84**:4713–21.
- [16] George MM, Ten New MIS, Sultan C. The clinical and molecular heterogeneity of 17BHSD-3 enzyme deficiency. *Horm Res Paediatr* 2010;**74**:229–40.
- [17] Rosler A, Silverstein S, Abeliovich D. A (R80Q) mutation in 17-beta-hydroxysteroid dehydrogenase type 3 gene among Arabs of Israel is associated with pseudohermaphroditism in males and normal asymptomatic females. *J Clin Endocrinol Metab* 1996;**81**:1827–31.
- [18] Hughes IA, Houk C, Ahmed SF, Lee PA. Lawson Wilkins: pediatric endocrine society/European society for pediatric endocrinology consensus group. Consensus statement on management of intersex disorders. *J Pediatr Urol* 2006;**2**:148–62.
- [19] Flück CE, Pandey AV. Clinical and biochemical consequences of p450 oxidoreductase deficiency. *Endocr Dev* 2011;**20**:63–79.
- [20] Jini M, Sen S, Chacko J, Zachariah N, Raghupathy P, Mammen KE. Gender assignment in male pseudohermaphroditism: an Indian perspective. *Pediatr Surg Int* 1993;**8**:500–1.
- [21] Taha SA. Male pseudohermaphroditism. Factors determining the gender of rearing in Saudi Arabia. *Urology* 1994;**43**:370–4.
- [22] Rajerdan R, Hariharan S. Profile of intersex children in South India. *Indian Pediatr* 1995;**32**:666–71.
- [23] Tunçbilek E, Koç I. Consanguineous marriage in Turkey and its impact on fertility and mortality. *Ann Hum Genet* 1994;**58**:321–9.
- [24] Kandemir N, Yordam N. Congenital adrenal hyperplasia in Turkey: a review of 273 patients. *Acta Paediatr* 1997;**86**:22–5.
- [25] Hines M. Abnormal sexual development and psychosexual issues. *Baillieres Clin Endocrinol Metab* 1998;**12**:173–89.
- [26] MacLusky NJ, Naftolin F. Sexual differentiation of the central nervous system. *Science* 1981;**211**:1294–303.
- [27] Diamond M, Sigmundson HK. Management of intersexuality. Guidelines for dealing with persons with ambiguous genitalia. *Arch Pediatr Adolesc Med* 1997;**151**:1046–50.
- [28] Cohen-Kettenis PT. Gender change in 46,XY persons with 5alpha-reductase-2 deficiency and 17beta-hydroxysteroid dehydrogenase-3 deficiency. *Arch Sex Behav* 2005;**34**:399–410.
- [29] Partridge WM, Gorski RA, Lippe BM, Green R. Androgens and sexual behavior. *Ann Int Med* 1982;**96**:488–501.
- [30] Reiner W. To be male or female-that is the question. *Arch Pediatr Adolesc Med* 1997;**151**:224–5.
- [31] Warne GL, Bhatia V. Cultural differences and controversies about timing of management. In: Hutson JM, Warne GL, Grover SR, editors. *Disorders of sex development. An integrated approach to management*. Berlin, Heidelberg: Springer-Verlag; 2012. p. 215–30.
- [32] Jones HW, Park IJ, Rock JA. Technique of sex reassignment for micropenis and allied conditions. *Am J Obstet Gynec* 1978;**132**:870–7.
- [33] Hinman Jr F. Microphallus. caharacteristics and choice of treatment from a study of 20 cases. *J Urol* 1972;**107**:499–505.
- [34] Raisman G, Field PM. Sexual dimorphism in the preoptic area of the rat. *Science* 1971;**173**:20–2.
- [35] Udry JR. Putting prenatal effects on sex-dimorphic behavior in perspective: an absolutely complete theory. *Epidemiology* 2003;**14**:135–6.
- [36] Mayer A, Lahr G, Swaab DF, Pilgrim C, Reisert I. The Y-chromosomal genes SRY and ZFY are transcribed in adult human brain. *Neurogenetics* 1998;**1**:281–8.
- [37] Devecioglu D, Özbey H, Darendeliler F, Keles N, Korkmazlar Ü, Salman T. Transient evoked otoacoustic emissions in children with intersex disorders. In: XVIth international symposium of pediatric surgical research. Marseille, France, October 3–4, 2003 and XVth European Society for Pediatric Urology (ESPU), Regensburg, Germany April 21–24, 2004 [Abstract].
- [38] Etker S, Özbey H. Challenges in disorders of sex development: what specialized centers, societies and networks can provide. In: 8th international conference of benha children's hospital-BENCH VIII. Alexandria, Egypt, April 4–6, 2012. p. 18[Abstract].
- [39] Wiesemann C, Ude-Koeller S, Sinnecker GHG, Thyen U. Ethical principles and recommendations for the medical management of differences of sex development (DSD)/intersex in children and adolescents. *Eur J Pediatr* 2010;**169**:671–9.