



Unusual presentations of prostate cancer: A review and case reports

Ahmed Elabbady & Ahmed Fouad Kotb

To cite this article: Ahmed Elabbady & Ahmed Fouad Kotb (2013) Unusual presentations of prostate cancer: A review and case reports, Arab Journal of Urology, 11:1, 48-53, DOI: [10.1016/j.aju.2012.10.002](https://doi.org/10.1016/j.aju.2012.10.002)

To link to this article: <https://doi.org/10.1016/j.aju.2012.10.002>



© 2012 Arab Association of Urology



Published online: 05 Apr 2019.




Submit your article to this journal [↗](#)



Article views: 415



View related articles [↗](#)



ONCOLOGY/RECONSTRUCTION

Unusual presentations of prostate cancer: A review and case reports

Ahmed Elabbady, Ahmed Fouad Kotb *

Department of Urology, Alexandria University, Alexandria, Egypt

Received 15 September 2012, Received in revised form 29 October 2012, Accepted 29 October 2012

Available online 6 December 2012

KEYWORDS

Prostate cancer;
Supraclavicular lymph
node;
Hydronephrosis;
Constipation

Abstract Objective: To report our institutional experience with some rare presentations of prostate cancer, as prostate cancer is a common problem and affects a large group of men during their lifetime, but a few studies report unusual presentations of metastatic prostate cancer.

Methods: All possible clinical and pathological data were collected for six relevant patients with prostate cancer and unusual metastases who were identified at our institution. PubMed was searched for unusual presentations of prostate cancer in the last 20 years (1982–2012) and all relevant publications were assessed. The authors discussed the reports and selected those articles of major clinical significance to include in a review.

Results: We identified 19 reports of major clinical significance and reviewed them. As in the cases from our institution, supraclavicular lymphadenopathy, isolated upper ureteric obstruction and severe obstructing constipation were some of the rare presentations encountered at other institutions, and reported mostly as sporadic case-reports.

Conclusion: Prostate cancer should be always considered in the differential diagnosis of elderly men presenting with supraclavicular lymphadenopathy, hydronephrosis or constipation, even in the presence of a normal digital rectal examination and low serum total prostate-specific antigen (PSA) levels. PSA immunohistochemical staining should be used in doubtful cases.

© 2012 Arab Association of Urology. Production and hosting by Elsevier B.V. All rights reserved.

* Corresponding author. Tel.: +20 1203021316.

E-mail address: draahmedfali@gmail.com (A.F. Kotb).

Peer review under responsibility of Arab Association of Urology.



Production and hosting by Elsevier

Introduction

Prostate cancer is a common problem that in most cases starts to develop at the age of 50 years and reaches its peak incidence at 60–70 years of age. The prognosis of

prostate cancer mainly depends on the presence or absence of metastatic spread [1]. Prostate cancer usually metastasises to the bony skeleton, followed by lungs, liver, pleura and adrenal glands [2]. Rarely prostate cancer can present with non-regional lymph nodes or soft-tissue metastases, and such presentations are usually communicated as sporadic case-reports.

The aim of the present study was to review previous reports of unusual metastatic presentations of prostate cancer, and to report our experience with such cases.

Methods

All relevant clinical and pathological data were collected for six relevant patients identified at our institution. Medline was searched, using PubMed, for reports published in the last 20 years (1982–2012), focusing on unusual presentations of prostate cancer and using the keywords ‘prostate cancer’, ‘supraclavicular lymph node’, ‘hydronephrosis’, and ‘constipation’. All relevant publications were collected and the authors discussed choosing the articles of major clinical influences to include in our review.

Results

From our practice we identified several unusual presentations of metastatic prostate cancer.

Supraclavicular lymph node

The first case was a 57-year-old man who presented with a right hard supraclavicular mass, 2 cm in diameter, that was followed 2 months later by aphasia and right-sided hemi-paresis. During the 2-month period, the supraclavicular mass doubled in size. CT showed brain tumours affecting the left temporal, parietal and frontal lobes, that were suspected to be metastases. The patient had no urinary complaints, a DRE detected a hard irregular prostate (clinically T3), and the serum PSA level was 151 ng/mL. CT showed no abdominal or pelvic lymphadenopathy, but only diffuse skeletal metastases. We immediately started the patient on bicalutamide 150 mg daily with corticosteroids. Limited TRUS-guided prostatic biopsies confirmed the diagnosis of prostate cancer, Gleason 4 + 5 in all four cores that were taken. On the third day of treatment the patient had marked improvements in speech and in limb weakness. LHRH analogues were added to the treatment regimen. The supraclavicular mass regressed in size by $\approx 80\%$ after 2 weeks and disappeared completely after 8 weeks. The patient was followed up for > 18 months, on intermittent androgen blockade, and showing stable disease.

The second case was a 77-year-old man who presented to the urology clinic with acute urinary retention and a history of TURP, undertaken 4 years previously, with a pathology report of BPH. The DRE revealed a

hard, irregular prostate, and clinical T3 disease, with a serum PSA level of 180 ng/mL. CT of the abdomen and a bone scan showed no abnormality, with no skeletal metastases and no abdominal lymphadenopathy. A limited TURP and TRUS-guided prostatic biopsies detected prostate cancer of Gleason 4 + 5 in all six cores taken. Bicalutamide 50 mg/day was started, followed by an LHRH agonist, resulting in a good PSA response (reduced to 0.09 ng/mL). After 1 year of controlled disease the patient was followed while on intermittent androgen blockade. During the off-treatment period the patient presented with a large, hard and fixed left supraclavicular lymph node, with a PSA level of 12 ng/mL and no abnormality on CT of the abdomen or pelvis. The patient refused to have a biopsy from a neck mass. We restarted total androgen blockade, resulting in a good PSA response and complete resolution of the supraclavicular mass within 3 months. After another year of complete androgen blockade the patient chose to take the drug intermittently and he has been followed up to the present, with no evidence of progression of the supraclavicular mass.

The third case was a 76-year-old man who presented with a high PSA level (123 ng/mL) and locally advanced prostate cancer, classified as T3N2M0 disease. The TRUS-guided biopsy showed Gleason 4 + 3 in all four cores taken. The patient was treated with continuous total androgen blockade and conformal radiotherapy. However, 3 years later castration resistance started to emerge, and a right-sided hard supraclavicular mass appeared. We tried anti-androgen withdrawal, added ketoconazole and corticosteroids, and there was a partial biochemical and clinical response for a few months. After 6 months the patient was referred to medical oncology, and chemotherapy was started, allowing partial remission of the supraclavicular lymph node.

Ureteric adventitia

A 62-year-old man presented with left loin pain that had started a few months previously. Ultrasonography showed left-sided grade 3 hydronephrosis, and IVU confirmed a provisional diagnosis of PUJ obstruction. (Fig. 1). The patient had no LUTS and a DRE showed a hard irregular prostate, and the serum total PSA level was 142 ng/mL. Multi-slice CT showed a left peri-ureteric mass, enlarged left iliac and para-aortic lymph nodes, together with multiple lytic lesions in the vertebral spines. Fig. 2 shows the findings from CT. TRUS-guided prostatic biopsies confirmed the diagnosis of prostate cancer, Gleason 4 + 3. Bicalutamide 150 mg/day was started, followed later by injections with an LHRH analogue. At 2 weeks after the first dose of LHRH analogue IVU showed a marked improvement of the PUJ obstruction and the pain was resolved (Fig. 3).

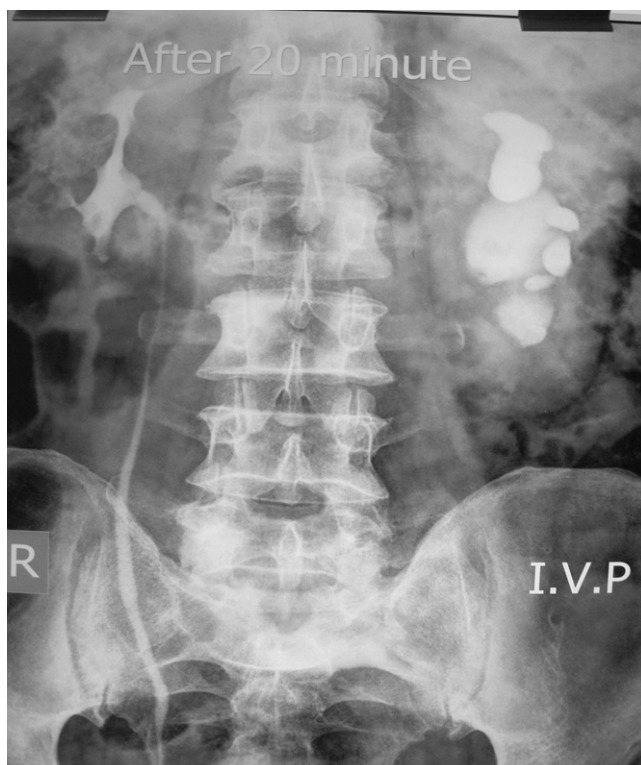

Figure 1 Initial IVU showing the left PUV obstruction.

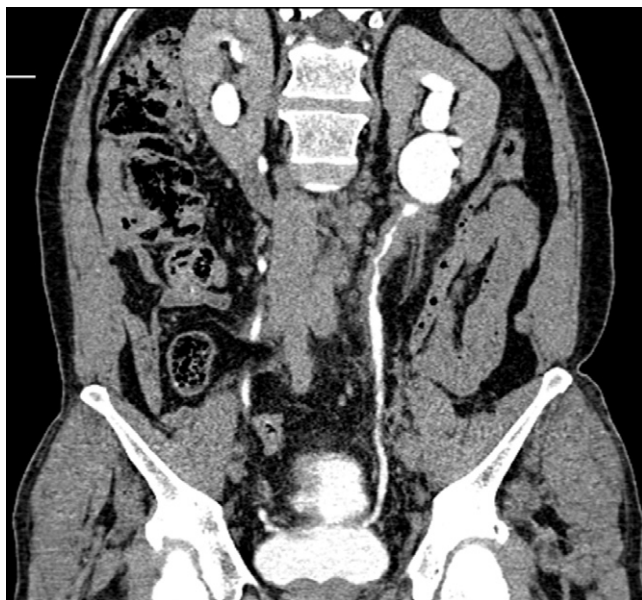


Figure 2 CT of the abdomen and pelvis, showing an extensive left peri-ureteric mass.

Constipation

We had two patients (70 and 62 years old) who both initially presented with severe constipation. MRI in the first patient showed a huge mass bulging into the rectum. The serum PSA level was 480 ng/mL and limited

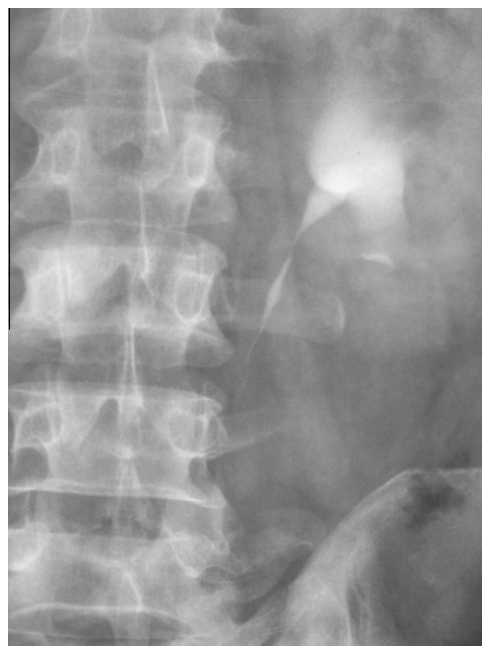

Figure 3 The follow-up IVU, after hormonal treatment, showing an improvement in the obstruction.

TRUS confirmed the diagnosis of prostate cancer, Gleason 3 + 4. A bone scan showed metastatic deposits. Immediate complete androgen blockade for 6 months resulted in a marked improvement in the patient's symptoms. The other patient presented to a general surgeon, who diagnosed advanced rectal carcinoma. The patient was wrongly managed with a colostomy, but he had no relief and presented to another general surgeon who, after examination, referred the patient for urological consultation. When examined the prostate was hard and hugely enlarged, with T4 disease. The PSA level was then 121 ng/mL, and TRUS biopsies confirmed a tumour of Gleason score 4 + 3. A bone scan showed deposits. Bilateral orchidectomy resulted in a marked improvement and the colostomy was closed.

Previous reports

We identified 19 publications of major clinical significance and included them in our review. As in the patients from our institution, they included supraclavicular lymphadenopathy, but also isolated upper ureteric obstruction and severe obstructing constipation as rare presentations encountered in different institutions, and communicated in most cases as sporadic case-reports.

Supraclavicular lymphadenopathy secondary to prostate cancer was the most discussed unusual presentation and we identified 16 reports of clinical significance. Most reports discussed possible dissemination to the left supraclavicular lymph nodes. One report described an isolated right supraclavicular nodal dissemination from prostate cancer. Of the three patients we identified with

prostate cancer one presented with right supraclavicular lymphadenopathy.

Soft-tissue metastases to the ureteric adventitia were of interest and we found two case reports of major clinical significance, as these cases were wrongly managed by nephroureterectomy. We found one case of upper ureteric adventitial spread from prostate cancer that was diagnosed before surgical intervention and progressed well on hormonal treatment.

A third interesting unusual presentation of prostate cancer was severe constipation, not responding to regular medications. We identified one report and describe two cases from our practice.

Discussion

Lymph nodes are commonly involved during the course of metastatic prostate cancer, with hypogastric and obturator lymph nodes as the most common sites [3]. Further spread can occur to the para-aortic nodes, to cisterna chili, to the thoracic duct, and then to the left subclavian vein, and to the systemic circulation [4]. Tumour cells can theoretically lodge in the left supraclavicular lymph nodes in a retrograde fashion. Batson [5] suggested that the supradiaphragmatic extension of prostate cancer occurs haematogenously via the vertebral venous system, or Batson's plexus, accessible via direct extension from the primary prostate cancer.

Supraclavicular lymph nodes are commonly affected during the course of metastasis of the lungs, head, neck, salivary glands and thyroid cancer [6]. Distant primaries rarely involving supraclavicular nodes include those in the kidney and the breast [6]. The incidence of involvement secondary to prostate cancer has been reported to be <0.4% as a part of widespread metastatic disease [7,8].

Few studies have indicated the possibility of supraclavicular lymph node involvement during the course of prostate cancer metastasis. Nearly all available publications reported an association of prostate cancer with the left supraclavicular lymph node, as a single metastasis or as a part of generalised lymphadenopathy.

Saeter et al. [9] studied 47 patients with carcinoma of the prostate, who at the time of diagnosis had soft tissue or non-regional lymph nodes involved. They reported that the left supraclavicular fossa was the most common site of extra-skeletal non-regional lymphatic spread, and the survival of such cases was similar to those presenting with skeletal metastases, and with an equal response to hormonal therapy. Platania et al. [10] reported a case of prostate cancer presenting with enlarged left supraclavicular lymph nodes. Biopsy showed an undifferentiated adenocarcinoma of unknown origin. PSA staining confirmed the diagnosis of prostate cancer.

Jones and Anthony [11] detected 11 patients with metastatic prostate cancer during a survey of 250 cervical lymph nodal biopsies from men. These cases represent 11% of all cases metastatic to the neck, and 20%

of left-sided metastases. They also found that the serum PSA level was not elevated in half of the patients presenting with supraclavicular nodal metastasis, confirming the need for specific tissue staining. Wang et al. [12] reported three cases of metastatic prostate cancer initially presenting with a left supraclavicular mass. One of them had an associated right supraclavicular mass. CT of the abdomen confirmed associated generalised lymphadenopathy. Ahn et al. [13] reported a case of prostate cancer in a 34-year-old man that initially presented with a diagnosis resembling lymphoma. This patient had bilateral supraclavicular and inguinal lymphadenopathy, associated with mediastinal, abdominal and pelvic lymphadenopathy. The patient had no urinary symptoms, a normal DRE, but a markedly elevated serum PSA level. The diagnosis was then confirmed by PSA immunohistochemical staining. There was a marked improvement in the patient's condition after a bilateral orchidectomy.

Tsujino et al. [14] reported a case of prostatic adenocarcinoma presenting with supraclavicular and mediastinal lymphadenopathy, with CT and fluorodeoxyglucose-positron emission tomography confirming no abnormalities in the prostate or pelvic lymph nodes. Their patient had no urinary symptoms. The patient had a good response after hormonal therapy. These authors raised concern about the possibility of misdiagnosing metastatic prostate cancer to supradiaphragmatic lymph nodes as lung cancer, with inappropriate treatment by chemotherapy.

Cho et al. [15] studied 26 cases of prostate cancer metastatic to supradiaphragmatic lymph nodes, including 15 with left supraclavicular lymph node involvement. They showed that nearly half of the cases had normal DRE findings and a normal serum PSA level. They concluded that metastatic prostate cancer should be excluded in men aged >45 years, even if there was no high serum PSA level and normal DRE findings. Few other authors reported sporadic case-reports of prostate cancer metastasising to the supraclavicular lymph nodes [16–18]; Table 1 lists the previous publications.

The present study is the second to report the right supraclavicular lymph node to be the single non-regional gross metastasis of prostate cancer, despite

Table 1 Studies describing supraclavicular lymphadenopathy, as rare metastases from prostate cancer.

Study	Regional lymphadenopathy	Laterality L/R	N cases
[10]	No	1/0	1
[12]	Yes	3/1	3
[13]	Yes	1/1	1
[14]	No	1/0	1
[15]	No	15/0	15
[16]	Yes	1/0	1
[17]	No	0/1	1
[18]	No	1/0	1
Present	Yes	1/2	3

the absence of abdominal and pelvic lymphadenopathy. Being only associated with brain metastases this might confirm the theory of Batson [3] of a vascular, rather than lymphatic, route of spread to the supradiaphragmatic lymph nodes. Our first patient had a high Gleason grade and large-volume prostatic tumour, but again the metastases showed a good response to hormonal therapy that persisted to the present. The second case represented recurrent disease during the off-treatment period of LHRH and bicalutamide, while the third case was associated with the start of castration-resistant disease. These cases also confirm that supraclavicular lymph node involvement responds to treatment in the same way as skeletal metastases. Our patients responded to alternative hormonal treatment and to chemotherapy in the same way as those with skeletal metastases.

Although we did not use immunohistochemical staining in the present cases, due to the association with a high PSA level and a known history of metastatic prostate cancer in two of them, we believe that it is important in all cases of a supraclavicular mass in elderly men, noting that most of these patients are not initially seen by urologists.

Ureteric adventitia as an unusual site of soft-tissue metastases from prostate cancer has been reported sporadically. Chalasanani et al. [19] reported a 68-year-old man who presented with LUTS and right loin pain. The diagnostic evaluation, including PSA analysis, TRUS-guided biopsies and cystoscopy, showed prostate cancer and bladder TCC. Ureteroscopy showed a suspicious stricture that was thought to be a possible upper tract TCC. After nephroureterectomy, it was confirmed pathologically to be metastatic prostate cancer, infiltrating the adventitia of the whole ureter to the renal pelvis. Jallad et al. [20] reported a case with a distal ureteric stricture, a normal DRE and a normal PSA level that was also diagnosed as a possible upper tract TCC. After nephroureterectomy this was also confirmed to be metastatic prostate cancer to the ureteric adventitia.

Our patient with ureteric obstruction was initially evaluated by a senior urologist who was preparing the patient for a left pyeloplasty. When the patient presented to our institution we followed the simple rule that a DRE in 62-year-old could indicate the correct diagnosis. This patient was fortunate to be diagnosed early before any surgical intervention, and we think that the message for every urologist is not to hurry a diagnosis, always use a DRE and always suspect metastatic prostate cancer in the differential diagnosis.

Another unusual presentation of prostate cancer is constipation. Yokota et al. [21] reported two cases, one of which was diagnosed by TRUS-guided biopsies and responded to hormonal treatment. The other was unfortunate in that he was managed by pelvic evisceration, and was subsequently confirmed pathologically to have locally advanced prostate cancer. Based on our

personal experience and our two cases, we think that every man presenting with constipation refractory to treatment should be assessed for possible locally advanced prostate cancer. One of our patients was unlucky to be managed wrongly by a diverting colostomy, and we understand that there might be others managed in the same way and who are still under-diagnosed.

In conclusion, prostate cancer should be always considered in the differential diagnosis of elderly men presenting with supraclavicular lymphadenopathy, hydronephrosis or constipation, even in the presence of a normal DRE and low serum total PSA level. PSA immunohistochemical staining should be used in doubtful cases. The DRE should not be ignored in any elderly man, regardless of the presenting symptoms and the provisional diagnosis.

Conflict of Interest

None.

Source of Funding

None.

References

- [1] Bubendorf L, Schöpfer A, Wagner U, Sauter G, Moch H, Willi N, et al. Metastatic patterns of prostate cancer: an autopsy study of 1,589 patients. *Hum Pathol* 2000;**31**:578–83.
- [2] Mundy GR. Metastasis to bone. Causes, consequences and therapeutic opportunities. *Nat Rev Cancer* 2002;**8**:584–93.
- [3] Saitoh H, Yoshida K, Uchijima Y, Kobayashi N, Suwata J, Kamata S. Two different lymph node metastatic patterns of a prostatic cancer. *Nat Rev Cancer* 1990;**65**:1843–6.
- [4] Cady B. Lymph node metastases. Indicators, but not governors of survival. *Arch Surg* 1984;**119**:1067–72.
- [5] Batson OV. The function of the vertebral veins and their role in the spread of metastasis. *Clin Orthop Relat Res* 1995;**312**:4–9.
- [6] Copeland B, Clark JM, Sura A, Kilpatrick SE, Shockley W, Meredith S. Prostate carcinoma metastatic to the cervical lymph nodes. Report of two cases and review of the literature. *Am J Otolaryngol* 2001;**22**:420–3.
- [7] Saitoh H, Hida M, Shimbo T, Nakamura K, Yamagata J, Satoh T. Metastatic patterns of prostate cancer: correlation between sites and number of organs involved. *Nat Rev Cancer* 1984;**54**:3078–84.
- [8] Flocks RH, Boatman DL. Incidence of head and neck metastases from genito-urinary neoplasms. *Laryngoscope* 1986;**83**:1527–39.
- [9] Saeter G, Fosså SD, Ous S, Blom GP, Kaalhus O. Carcinoma of the prostate with soft tissue or non-regional lymphatic metastases at the time of diagnosis: a review of 47 cases. *Br J Urol* 1984;**56**:385–90.
- [10] Platania M, Bajetta E, Guadalupi V, Buzzoni R, Colecchia M. Prostate adenocarcinoma presenting with supraclavicular node enlargement. Report of a case. *Tumori* 2008;**94**:769–71.
- [11] Jones H, Anthony PP. Metastatic prostatic carcinoma presenting as left-sided cervical lymphadenopathy. A series of 11 cases. *Histopathology* 1992;**21**:149–54.
- [12] Wang HJ, Chiang PH, Peng JP, Yu TJ. Presentation of prostate carcinoma with cervical lymphadenopathy: report of three cases. *Chang Gung Med J* 2004;**27**:840–4.

- [13] Ahn MJ, Oh SJ, Lee YY, Jung TJ, Kim IS, Choi IY, et al. A case of prostate cancer in 34-year-old man presenting with generalized lymphadenopathy mimicking malignant lymphoma. *J Korean Med Sci* 1997;**12**:262–5.
- [14] Tsujino K, Sasada S, Kawahara K, Terada H, Komori C, Suzuki H, et al. A case of prostatic adenocarcinoma clinically presenting as supraclavicular and mediastinal lymphadenopathy. *Nihon Kokyuki Gakkai Zasshi* 2007;**45**:648–53.
- [15] Cho KR, Epstein J. Metastatic prostatic carcinoma to supradiaphragmatic lymph nodes, a clinicopathologic and immunohistochemical study. *Am J Surg Pathol* 1987;**11**:457–63.
- [16] Woo K, Wiczorek R, Torre P, Lepor H. Prostate adenocarcinoma presenting as a large supraclavicular mass. *Rev Urol* 2001;**3**:102–5.
- [17] Ozgür A, Ilker Y, Türkeri LN. Cervical lymph node enlargement on the right side as the initial manifestation of metastatic prostate cancer. *Arch Esp Urol* 2003;**56**:859–61.
- [18] Carleton J, van der Riet P, Dahm P. Metastatic prostate cancer presenting as an asymptomatic neck mass. *Prostate Cancer Prostatic Dis* 2005;**8**:293–5.
- [19] Chalasani V, Macek P, O'Neill GF, Barrett W. Ureteric stricture secondary to unusual extension of prostatic adenocarcinoma. *Can J Urol* 2010;**17**:5031–4.
- [20] Jallad S, Turo R, Kimuli M, Smith J, Jain S. Ureteric stricture. An unusual presentation of metastatic prostate adenocarcinoma. *Ann R Coll Surg Engl* 2012;**94**:213–4.
- [21] Yokota N, Hashimoto Y, Iida S, Kondo T, Goya N, Toma H, et al. Two cases of prostatic carcinoma causing a disorder of gastrointestinal transit due to rectal stenosis. *Hinyokika Kyo* 2009;**55**:517–21.