



Presentation and Management Outcome of Anterior Fontanelle Dermoid Cyst: Report of 6 Cases

Lawal Barau Abdullahi ^{a*} and Ibrahim Abdu ^b

^a Department of Surgery, Bayero University Kano, Nigeria.

^b Khalifa Isyaka Rabiou Specialist Hospital Kano, Nigeria.

Authors' contributions

This work was carried out in collaboration between both authors. Both authors read and approved the final manuscript.

Article Information

DOI: <https://doi.org/10.9734/ajmah/2024/v22i101108>

Open Peer Review History:

This journal follows the Advanced Open Peer Review policy. Identity of the Reviewers, Editor(s) and additional Reviewers, peer review comments, different versions of the manuscript, comments of the editors, etc are available here: <https://www.sdiarticle5.com/review-history/116663>

Case Report

Received: 10/03/2024

Accepted: 13/05/2024

Published: 15/10/2024

ABSTRACT

Aim: The aim of study is highlight the presentation of anterior fontanelle Dermoid cyst which is relatively uncommon condition, and our ability to excised the cysts in our resource poor environment.

Presentation of Cases: A retrospective study of all the consecutive patients managed by pediatric surgery unit over six years was done and the results was analysed and documented.

A total of six patients was managed over a period of five years including 4 boys and 2 girls. The age ranges between 6months to five years.

Discussion: Dermoid cysts are inclusion cyst mostly seen in the midline. 1, 2 They occur in head and neck or the trunk. It is a benign, slowly growing lesion, dermoid cysts are thought to arise during the third and fifth week of embryogenesis from displacement of germ cells during the formation of the neural tube.

All of the patients had excision under general anesthesia. The intra operative finding is a global, cystic swelling containing amber to yellow color jelly fluid.

*Corresponding author: E-mail: a.lawalbarau@yahoo.com;

All the patients were operated as day case surgery and were discharged home about four to six hours after recovery from anesthesia. All the patients did well postoperatively, only one patient had surgical site infection which was treated with antibiotics and wound dressing.

Conclusion: Dermoid cyst is an uncommon congenital cyst mostly diagnosed during infancy, following excision recurrence is uncommon.

Keywords: Dermoid cysts; anterior fontanel; congenital cyst; germ cells.

1. INTRODUCTION

Dermoid cysts are inclusion cyst mostly seen in the midline [1,2]. They occur in head and neck or the trunk. It is a benign, slowly growing lesion, dermoid cysts are thought to arise during the third and fifth week of embryogenesis from displacement of germ cells during the formation of the neural tube, the cyst is thought to be formed from defects in the separation of neuroectoderm, resulting in sequestration of ectodermal remnants [3,4].

The incidence rates of scalp dermoid cysts range from 15 to 22% [5,6] scalp dermoid involving the anterior fontanelle is rare [7]. It is a congenital lesion hence mostly present at birth or notice few month after birth, with a swelling that is slowly increasing in size [8,9]. Differential diagnosis of anterior Dermoid cyst includes scalp lipoma, scalp abscess, encephalocele, etc.

2. CASES PRESENTATION

Between January 2017 to December 2021 six (6) children were managed by pediatric surgery unit,

comprises four boys and two girls (Fig. 1). The age ranges between 6 month to five years. The commonest complain at presentation is scalp swelling which is painless slowly increasing in size (Fig. 2). Only one patient has fever at presentation which was treated with anti-malarial and paracetamol before the surgery, two patients also had anemia with packed cell volume of less than 30% and were optimized with hematinic before the surgery.

All of the patients had excision under general anesthesia. The intra operative finding is a global, cystic swelling containing amber to yellow color jelly fluid (Fig. 3B). All the patients were operated as day case surgery and were discharged home about four to six hours after recovery from anesthesia. All the patients did well postoperatively, only one patient had surgical site infection which was treated with antibiotics and wound dressing. None of the patients had recurrence throughout the follow up period, though the last patient was followed up for only six month before the end of the study period.

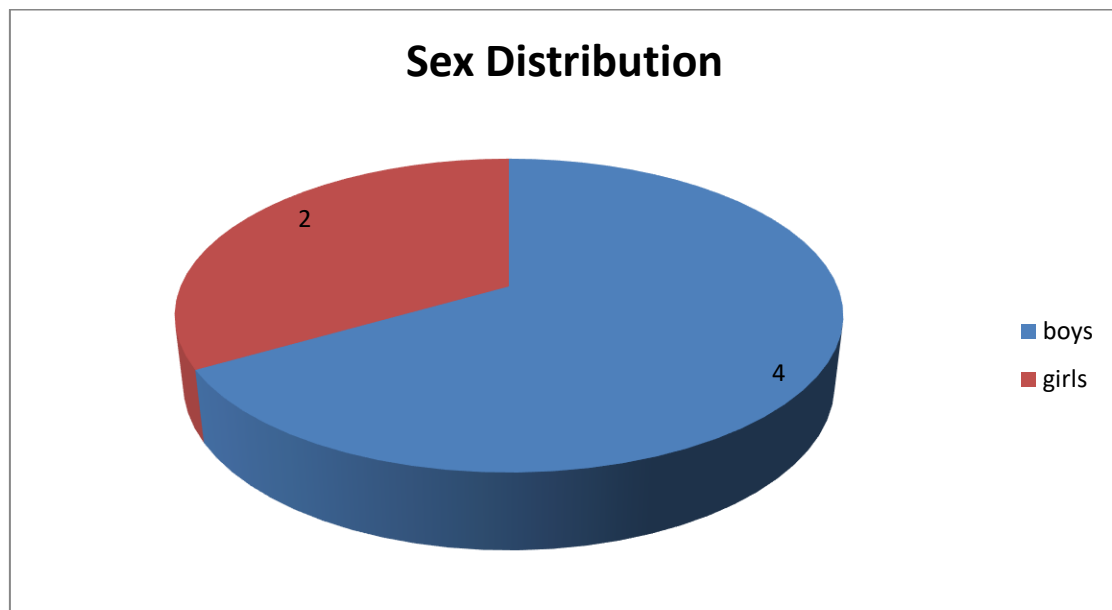


Fig. 1. Pie chart showing sex distribution

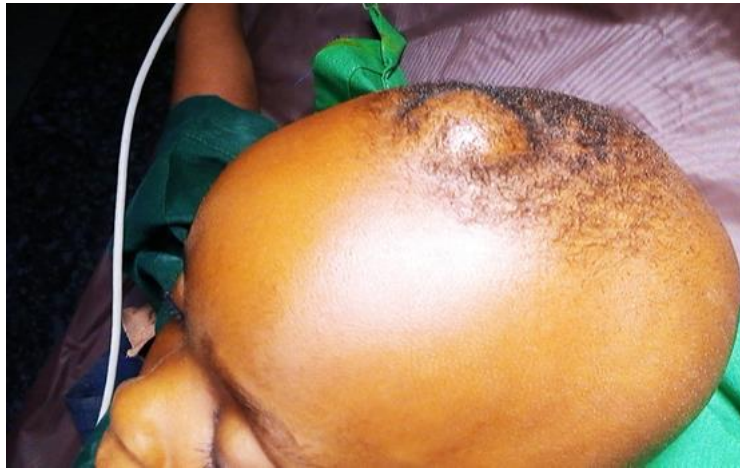

Fig. 2. Pre- operative picture

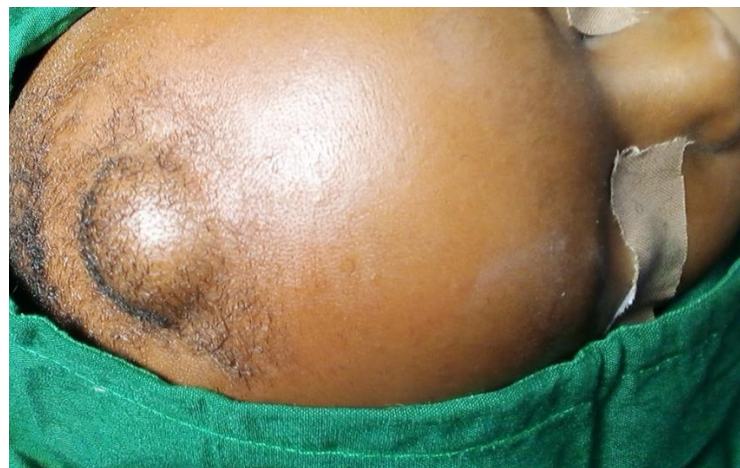

Fig. 3A. Intra – operative picture (before incision)

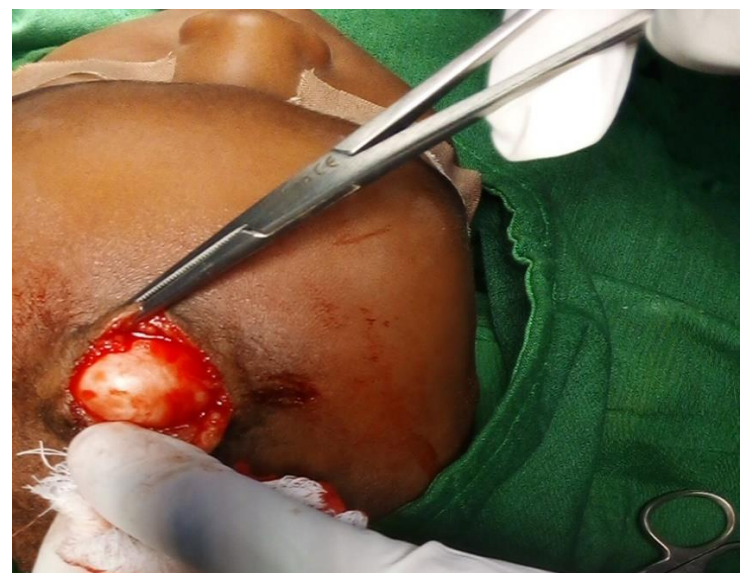


Fig. 3B. Intra – operative picture

3. DISCUSSION

Dermoid cyst are subcutaneous sacs lined with a stratified squamous epithelium consists of semi-solid inspissated yellow material [4]. The contents of the cyst are commonly hair and hair follicle, sebaceous glands rarely presence of sweat gland is also reported in the literature [5]. This is confirmed histologically in most of our pathologic samples.

The common symptoms at presentation in our patients is painless scalp swelling around the anterior fontanelle which is slowly increasing in size, this is similar to most of documented findings in other studies worldwide [7]. usually there are no constitutional symptoms except infected or in the present of trauma which is consistent with the features we found among our patients only 1patient had fever [8,9]. They are usually round cystic masses that are non-tender, the affected children are otherwise healthy.

The diagnosis is usually clinical from history and examination, however some investigations may be done to confirm the presence of a cystic mass at the anterior fontanelle or presence of intracranial extension of the cyst, these includes high resolution ultrasound, scalp computer tomography (CT) or scalp Magnetic resonance imaging (MRI) [8,9,10].

All of our patients had subcutaneous ultrasound studies which showed a cystic swelling around the anterior fontanelle.

The most widely used method of treatment is surgical excision, and recurrence after excision is said to be very low. All of the patients in our study had surgical excision under general anesthesia and none of them had recurrence due period of the follow up [10,11].

4. CONCLUSION

Dermoid cyst is a congenital cyst mostly diagnosed during infancy, following excision recurrence is uncommon.

DISCLAIMER (ARTIFICIAL INTELLIGENCE)

Author(s) hereby declare that NO generative AI technologies such as Large Language Models (ChatGPT, COPILOT, etc) and text-to-image

generators have been used during writing or editing of manuscripts.

CONSENT

As per international standards, parental written consent has been collected and preserved by the author(s).

ETHICAL APPROVAL

It is not applicable.

COMPETING INTERESTS

Authors have declared that no competing interests exist.

REFERENCES

1. Asra Tanwir, Noor Malik, Gohar Javed, Romana Idrees. Dermoid cyst with no intracranial extension: A case report and literature review. 28-Feb-2019;10:25.
2. Adouani A, Chennoufi M, Hammoud M, Zribi A, Ben Salem A, Zitouni K et al. Malignant transformation of a dermoïd cyst of the scalp: A case report. *Tunis Med.* 2004;82:972-5.
3. Agrawal A, Santhi V, Reddy V. Subgaleal dermoid cyst of the anterior fontanelle in a child. *Egypt J Radiol Nucl Med.* 2015;46: 1171-4.
4. Iwamuro Y, Shirahata M, Jito J, Tokime T, Hosotani K, Tokuriku Y. A case report of a scalp dermoid cyst containing watery-clear fluid. *No Shinkei Geka.* 2002;30:211-4.
5. Peter JC, Sinclair-Smith C, de-Villiers JC Midline dermal sinuses and cysts and their relationship to the central nervous system. *Eur J Pediatr Surg.* 1991;1:73-9.
6. Tan EC, Takagi T. Congenital inclusion cysts over the anterior fontanelle in Japanese children. A study of five cases. *Childs Nerv Syst.* 1993;9:81-3.
7. Makhija D, Sisodiya N, Shah H, Waghmare M. Cystic congenital scalp inclusion dermoid: A case report. *Dev Period Med.* 2016;20:287-8.
8. Kumar S, Singh M, Agarwal P. Giant congenital dermoid cyst of scalp. *J Cran Max Dis.* 2014;3:147-9.

9. Udina C, Calligaris L, Berti I, Cattaruzzi E, Barbi E. Inclusion cyst of anterior fontanelle. *sArch Dis Child*. 2020;105:95.
10. de Aquino HB, de Miranda CC, de Britto Filho CA, Carelli EF, Borges G. Congenital dermoid inclusion cyst over the anterior fontanel: report of three cases. *Arq Neuropsiquiatr*. 2003;61:448–452.
11. Ramnarayan R, Mariappan M. Dermoid Cysts of the Anterior Fontanel in Adults. *J Neurosci Rural Pract*. 2018;9:448–449.

Disclaimer/Publisher's Note: The statements, opinions and data contained in all publications are solely those of the individual author(s) and contributor(s) and not of the publisher and/or the editor(s). This publisher and/or the editor(s) disclaim responsibility for any injury to people or property resulting from any ideas, methods, instructions or products referred to in the content.

© Copyright (2024): Author(s). The licensee is the journal publisher. This is an Open Access article distributed under the terms of the Creative Commons Attribution License (<http://creativecommons.org/licenses/by/4.0>), which permits unrestricted use, distribution, and reproduction in any medium, provided the original work is properly cited.

Peer-review history:

The peer review history for this paper can be accessed here:

<https://www.sdiarticle5.com/review-history/116663>