

## Case Report



# Is there a link between COVID-19 and Creutzfeldt-Jakob Disease? a Case Report

Ehsan Nasiri<sup>1</sup>, Amirreza Naseri<sup>1</sup>, Mohammad Yazdchi<sup>2</sup>, Mahnaz Talebi<sup>2\*</sup>

<sup>1</sup>Student Research Committee, Tabriz University of Medical Sciences, Tabriz, Iran

<sup>2</sup>Neurosciences Research Center (NSRC), Tabriz University of Medical Sciences, Tabriz, Iran

### Article info

#### Article History:

Received: 13 Feb. 2021

Accepted: 22 Feb. 2021

e-Published: 25 May 2021

#### Keywords:

- Creutzfeldt-Jakob disease
- CJD
- COVID-19
- Case report

### Abstract

Creutzfeldt-Jakob disease (CJD) is a rare rapidly progressive neurodegenerative disease. The diagnosis of CJD is based on magnetic resonance imaging (MRI) findings, electroencephalography (EEG), or 14-3-3 protein detection. We report a case of a previously-healthy 72 year-old woman, with evidence of coronavirus disease 2019 (COVID-19), who complained of behavioral changes and rapidly progressive dementia. While hospitalized, she did not have orientation to time and place and repeated an irrelevant sentence in response to questions. Also, anomia and impaired comprehension was observed. Myoclonic jerks, abnormal signal intensity at bilateral parieto-occipital cortices in MRI, periodic sharp wave complexes in EEG, and increased lactate dehydrogenase in cerebrospinal fluid (CSF) highly recommended CJD as the diagnosis. This is the second case of CJD after COVID-19 during this pandemic, which can be an alarm to clinicians about the silent impact of COVID-19 on the central nervous system.

### Introduction

In the first months of 2020, the outbreak of a novel coronavirus, called Respiratory severe acute syndrome coronavirus 2 (SARS-CoV-2), impressed all the world society. The first system that coronavirus disease 2019 (COVID-19) affects is usually the respiratory system, although other systems in the body are also involved.<sup>1</sup> Fever, dry cough, and tiredness are defined as the most common symptoms of COVID-19. Some fewer common symptoms include vomiting, diarrhea, conjunctivitis, and neurologic signs like headache, myalgias, dizziness, dysgeusia, anosmia, and loss of taste or smell reported in various studies.<sup>2,3</sup> In the case of current infection, SARS-CoV-2 can be detected by polymerase chain reaction (PCR) test via both nasal and saliva samples. Also, in the case of pulmonary involvement, a chest x-ray, and a computerized tomography scan (CT scan) can be helpful for diagnosis. Some non-specific inflammatory factors like high level C-reactive protein (CRP) and Lactate dehydrogenase (LDH) in serum also can show inflammation in patients' bodies, which can be associated with COVID-19. Detection of Immunoglobulin G (IgG) and Immunoglobulin M (IgM) antibodies are used for early screening of COVID-19 to detect past infections. IgM can be detected in 3-5 days after onset and IgG in 7 days.<sup>4-6</sup>

The neuroinvasive capacity of coronaviruses is not well known. There is not enough information about the

neuropathogenesis of SARS-CoV-2. Reported loss of smell and hearing in COVID-19 patients, besides more common neurological manifestations, worried the clinicians about the SARS-CoV-2 effect on neurons. A 0.04% rate of neurologic symptoms in SARS and a 0.2% rate in the Middle East respiratory syndrome-related coronavirus (MERS)<sup>7</sup> besides the evidence that SARS-CoV-2 can infect neurons<sup>8</sup> makes the concerns even more. In addition to the direct way, there are possible mechanisms suggested for indirectly mediated inflammation and the neuralgic manifestation of COVID-19.<sup>9</sup> Overstimulation of the immune system is one of these mechanisms. Also, increased risk of stroke is one of the symptoms which should be considered about the disease.<sup>10</sup> A recent systematic review found a 1.7% pooled incidence of ischemic stroke in COVID-19 patients.<sup>11</sup> It seems that central and peripheral nervous system manifestations are neglected symptom associated with this infection.

Encephalitis is one of the rare complications of COVID-19. A systematic review of nine reports summarized all the cases of encephalitis due to COVID-19. Totally, 14 cases of this manifestation were reported in this study from which only six of the reported cases had encephalitis according to brain CT and magnetic resonance imaging (MRI).<sup>12</sup> A study in a Chinese setting found cognitive impairments in patients recovered from COVID-19 compared to the controls. In this study, some cognitive tests were correlated with serum CRP level.<sup>13</sup>

\*Corresponding Author: Mahnaz Talebi, Email: Talebi511@yahoo.com

A study in the United States found that neurological manifestations occurred in most of hospitalized patients and it was associated with increased morbidity and mortality.<sup>3</sup>

COVID-19's possible effect on accelerating neurodegeneration and Creutzfeldt-Jakob disease (CJD) was reported in the United States for the first time in a previously healthy man, whose symptoms started with confusion and delirium, progressed to paucity of speech over two weeks, and died after 2 months.<sup>14</sup> CJD is a rare rapidly progressive neurodegenerative disease and the commonest form of human prion disease caused by the accumulation of abnormal proteins in the neurons of central nervous system.<sup>15</sup> Usually, CJD appears in patients with 55-75 years old, and in about 90% of cases, leads to death over one year.<sup>16</sup> Myoclonus is the characteristic feature of CJD, but it can be presented with unstable gait, personality and behavioral changes, failing memory, and unstable gait, too. According to the updated clinical diagnostic criteria for CJD, parietal, occipital, and temporal cortical regions are the most valuable areas for diagnosis in MRI. Hyperintensities in at least two of these regions are of the same level of diagnostic importance with sharp wave complexes on the electro-encephalography (EEG) or 14-3-3 protein detection in the cerebrospinal fluid (CSF).<sup>17</sup> Moreover, increase in LDH level of CSF might be helpful to discriminate between CJD and other dementias.<sup>18</sup>

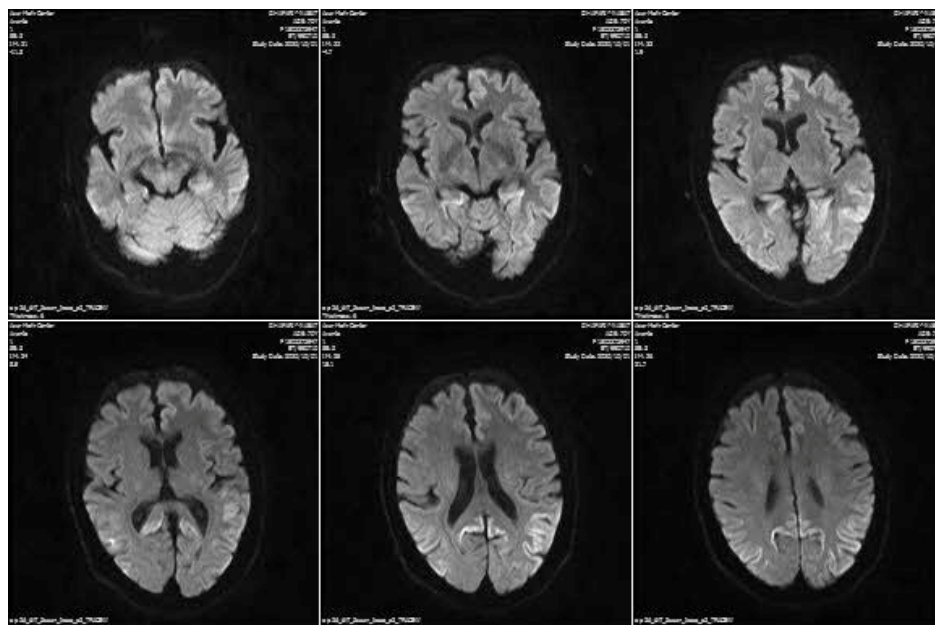
### Case Report

A 72 year-old previously healthy woman was complaining of fever and loss of smell about 30 days before hospitalization. The lung CT scan, lymphopenia, and the positive result of the COVID-19 Immunoglobulin G

(IgG) test suggested a recent COVID-19 for her. After two weeks, the first signs of disorientation to place and obsessive behaviors appeared. The condition became more severe and she could not recognize her family members. She was hospitalized and during hospitalization, she did not have an orientation to time and place, and repeated an irrelevant sentence in response to questions. She did not look at the examiner and looked around, aimlessly. Anomia and impaired comprehension were also observed. Cranial nerves were normal and there was no paresis. She did not express hunger or thirst, but when she was given food, she ate it. Myoclonic movements were also observed during her hospital confinement period.

The patient's first time MRI on October 1, 2020 detected no abnormality; but in the second time axial T2/FLAIR, sagittal T2, and coronal T1/W brain MRI, on October 5, 2020, abnormal signal intensity was seen at bilateral parieto-occipital cortices which showed restriction of diffusion on DWI. In the third MRI, in additional DWI, there was bilateral cortical restricted diffusion in posterior aspects of parietal lobes and parietooccipital regions as well as some restriction in the left frontal cortex in brain MRI (Figure 1), but brain MRI with contrast did not show any enhancement. The report of the patient's EEG on October 12, 2020 only found that background rhythm was mildly slow (7c/s) without asymmetry, but her second and third EEG on October 24, 2020 and November 10, 2020 showed signs of periodic sharp wave complexes (Figure 2). Abnormal signal intensity at bilateral parieto-occipital cortices, triphasic discharges in EEG, and rapidly progressive dementia beside myoclonus, highly recommended CJD as the diagnosis for our patient.

The results of all routine biochemistry, hematology,



**Figure 1.** Brain MRI findings: Diffusion weight images, bilateral cortical restricted diffusion in posterior aspects of parietal lobes and parieto-occipital regions as well as some restriction in the left frontal cortex.

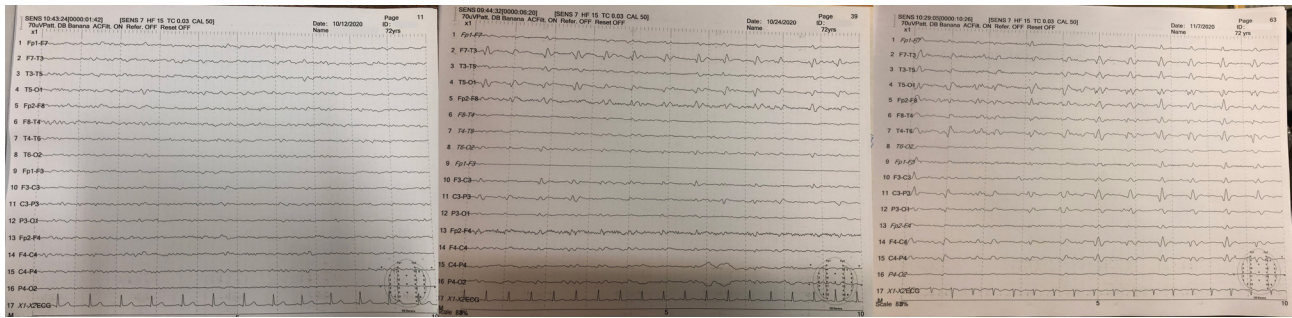


Figure 2. EEG findings on October 12, October 24 and November 10.

serology, hormone tests, count blood cell (CBC), nasal PCR test, and lumbar puncture (LP) analysis are summarized in Table 1. The result of the patient’s last nasal and PCR of CSF was negative but her LDH level

of CSF was at a high level, which can be due to CJD<sup>18</sup>. During hospitalization, the patient was treated with high-dose (2gr/kg) corticosteroids, plasmapheresis (250cc/kg), and intravenous immunoglobulin (IVIG) before the

Table 1. Results of all routine biochemistry, hematology, serology, hormone tests, count blood cell (CBC), nasal PCR and lumbar puncture test of the patient.

Test	Result	Reference Value		
<b>Blood Biochemistry (September, 12)</b>				
Fasting blood glucose	101 mg	70 – 110		
Urea	45 mg	15 – 55		
Creatinine	1.1 mg	0.6 – 1.4		
Uric Acid	5.9 mg/dl	2.6 – 6		
Triglycerides	96 mg/dl	40 – 200		
Cholesterol	214 mg/dl (high)	>200 high risk		
HDL	46 mg/dl	>34 desirable		
LDL	149 mg/dl	130 – 159 borderlines high		
AST	14 IU/L	Up to 40		
ALT	8 IU/L	5 – 41		
Alkaline phosphatase	215 IU/L	Up to 270		
Calcium	7.5 mg/dl (Low)	8.6 – 10.6		
Vitamin D <sub>3</sub>	40 ng/ml	30 – 100 sufficient		
<b>Hematology CBC</b>				
	<b>September, 12</b>	<b>September, 23</b>	<b>October, 9</b>	
W.B.C.	5 * 10 <sup>3</sup> /µl	4.5 * 10 <sup>3</sup> /µl	11.5 * 10 <sup>3</sup> /µl	4 – 10
Lymphocyte	26%	29.4%	8.2%	8-33%
Lymphocyte Count	1.3 * 10 <sup>3</sup>	1.32 * 10 <sup>3</sup>	0.94 * 10 <sup>3</sup>	0.8-5
R.B.C.	4.44 * 10 <sup>6</sup> /µl	4.48 * 10 <sup>6</sup> /µl	4.59 * 10 <sup>6</sup> /µl	3.8 – 6
HGB	13.3 g/dl	13.8 g/dl	13.5 g/dl	12 – 16
HCT	38.8%	38.1%	41.4%	33 – 50
M.C.V.	87 fL	85 fL	90 fL	80 – 100
M.C.H.	30 pg	31 pg	29 pg	25 – 32
M.C.H.C.	34 g/dl	36 g/dl	33 g/dl	28 – 40
Platelets	132 (Low)	135 (Low)	160	150 – 450
MPV	11.1 fL (High)	8.9 fL	11.1 fL	7 – 11
RDW	-	-	13.5 %	11.5 – 15
PDW	-	-	16.0 Fl	10 – 17
P-LCR	-	-	34.6 %	17 – 45

Table 1. Continues

Test	Result	Reference Value
<b>Serology (September, 23)</b>		
CRP	Negative	Up to 6.0
RF	Negative	Up to 8
<b>Immunoassays thyroid function (September, 23)</b>		
TSH	1.17 mIU/L	0.32 – 5.2
Free T4	1.32 ng/dL	0.8 – 2.1
<b>Immunoglobulins (September, 23)</b>		
COVID-19 IgM	0.44	<0.9 negative
COVID-19 IgG	12.66 (High)	>1.1 positive
<b>Routine Biochemistry (October, 9)</b>		
LDH	457 IU/L	Up to 480
Total protein	6.6 g/dl	6.6 – 8.7
Albumin	4.2 g/dl	3.5 – 5.2
<b>Nasal PCR (October, 10)</b>		
COVID-19 PCR	Negative	-
<b>Lumbar Puncture (October, 14)</b>		
COVID-19 PCR	Negative	-
W.B.C	Negative	-
R.B.C	Negative	-
Glucose	82	-
LDH	102 (High)	Up to 22
Protein	42	-

Abbreviations: HDL: High-density lipoprotein; LDL: Low-density lipoprotein; AST: Aspartate transaminase; ALT: Alanine aminotransferase; W.B.C.: White Blood Cell; R.B.C.: Red Blood Cell; HGB: hemoglobin; HCT: hematocrit; M.C.V.: Mean corpuscular volume; M.C.H.: Mean corpuscular hemoglobin; M.C.H.C.: Mean corpuscular hemoglobin concentration; MPV: Mean platelet volume; RDW: Red blood cell distribution width; PDW: Platelet Distribution Width; P-LCR: Platelet larger cell ratio; CRP: C-reactive protein; RF: rheumatoid factor; TSH: thyroid-stimulating hormone; IgM: Immunoglobulin M; IgG: Immunoglobulin G; LDH: Lactate dehydrogenase; COVID-19: coronavirus disease 2019; PCR: polymerase chain reaction;

suggestion of CJD, but there was no improvement and she discharged with consent in vegetative state. Her myoclonic seizure had worsened and treatment with valproate and levetiracetam was not associated with significant improvement.

## Discussion

From the first days of the COVID-19 epidemic in China, neurologic manifestations such as myalgia, headaches, and dizziness were reported as symptoms associated with this infection. Despite the reported cases of encephalitis<sup>12</sup> and cognitive impairments,<sup>13</sup> here we provide a detailed report of a case with probable CJD after COVID-19. This is the second case of CJD after SARS-CoV-2 infection. The earlier case was reported in the United States, in July 2020.<sup>14</sup> There is a little information about the possible underlying mechanisms, but the systemic inflammatory mediators may accelerate prion propagation which leads to rapid neurodegeneration. There is no definite treatment for CJD.<sup>16</sup>

The differential diagnosis of observed rapidly progressive dementia seen in the patient include CJD, atypical

presentations of other neurodegenerative disorders, autoimmune encephalopathies, some infections, and neoplasms. Autoimmune encephalopathies usually affect the limbic system and typically present with memory loss or behavioral changes. Viral encephalopathies are preceded by a flulike illness.<sup>19</sup> The discussed patient did not answer to corticosteroids and IVIG which can rule out the autoimmune diagnosis. Although there is not enough evidence for definite diagnosis of CJD, ruling out the other differential diagnosis and numerous evidences in favor of CJD diagnosis like the LDH level of CSF, MRI and EEG findings, and myoclonus movements make CJD as the most probable diagnosis.

The annual incidence of CJD is approximately 1 per million. However, a previously reported case and our patient may indicate that infection with SARS-CoV-2 precipitates the neurodegeneration process. CJD is caused by the accumulation of abnormally-folded isoforms of cellular sialoglycoprotein. The accumulation of this prion protein leads to vacuolation and spongiform neuropathologic alterations with rapid neurodegeneration in affected regions. Animal studies have shown that there

is a rapid shift from preclinical to clinical stages of prion disease in association with some infections.<sup>20</sup> In prion disease, A1 reactive astrocytes act as serving foci for prion protein scrapie propagation and are neurotoxic. In the change of preclinical CJD to the clinical phase, region-specific homeostatic astrocytes are replaced by a neuroinflammatory transcriptome that impacts the astrocyte subpopulations.<sup>20</sup> Inflammatory factors, such as tumor necrosis factor (TNF), interleukin-1 (IL1), and complement component 1q (C1q) are necessary for A1 astrocytes activity, and increased secretion of these inflammatory factors is shown in COVID-19.<sup>21</sup> So, COVID-19 may accelerate the CJD pathogenesis. Nevertheless, considering the incidence of CJD and about 90 million documented cases of COVID-19, it would be expected that these illnesses could occur just simultaneously, too.

### Conclusion

After months, COVID-19 is still continuing to grow. A large number of death cases should not make us neglecting patients with mild physical illness. Asymptomatic infected people are at risk, too. Besides the governmental protocols for reducing the spreading of COVID-19, clinicians and researchers should consider all aspects of the disease, including vulnerability to later cognitive decline and dementia and even rare conditions like CJD to make it possible to cross this pandemic with the least complications.

### Conflict of Interest

The authors declare that they have no conflict of interest.

### Ethical approval

The patient's relatives were informed about this report and the signed informed consent was taken.

### Author's Contributions

EN write the first draft of the manuscript and AN, MY and MT critically read and edit. MY and MT were in the patient's treatment team. AN and EN took and edited the pictures and prepare them for submission. All of the authors approved the final version for submission.

### Acknowledgements

None.

### Funding

None.

### References

1. Yuki K, Fujiogi M, Koutsogiannaki S. COVID-19 pathophysiology: a review. *Clin Immunol.* 2020;215:108427. doi: 10.1016/j.clim.2020.108427.
2. Kaur N, Gupta I, Singh H, Karia R, Ashraf A, Habib A, et al. Epidemiological and clinical characteristics of 6635 COVID-19 patients: a pooled analysis. *SN Compr Clin Med.* 2020;1-5. doi: 10.1007/s42399-020-00393-y.
3. Liotta EM, Batra A, Clark JR, Shlobin NA, Hoffman SC, Orban ZS, et al. Frequent neurologic manifestations and encephalopathy-associated morbidity in Covid-19 patients. *Ann Clin Transl Neurol.* 2020;7(11):2221-30. doi: 10.1002/acn3.51210.
4. Wiersinga WJ, Rhodes A, Cheng AC, Peacock SJ, Prescott HC. Pathophysiology, transmission, diagnosis, and treatment of coronavirus disease 2019 (COVID-19): a review. *JAMA.* 2020;324(8):782-93. doi: 10.1001/jama.2020.12839.
5. Tang YW, Schmitz JE, Persing DH, Stratton CW. Laboratory diagnosis of COVID-19: current issues and challenges. *J Clin Microbiol.* 2020;58(6):e00512-20. doi: 10.1128/jcm.00512-20.
6. Zhong L, Chuan J, Gong B, Shuai P, Zhou Y, Zhang Y, et al. Detection of serum IgM and IgG for COVID-19 diagnosis. *Sci China Life Sci.* 2020;63(5):777-80. doi: 10.1007/s11427-020-1688-9.
7. Ellul MA, Benjamin L, Singh B, Lant S, Michael BD, Easton A, et al. Neurological associations of COVID-19. *Lancet Neurol.* 2020;19(9):767-83. doi: 10.1016/s1474-4422(20)30221-0.
8. Mesci P, Macia A, Saleh A, Martin-Sancho L, Yin X, Snethlage C, et al. Sofosbuvir protects human brain organoids against SARS-CoV-2. *bioRxiv.* 2020. doi: 10.1101/2020.05.30.125856.
9. Yachou Y, El Idrissi A, Belapasov V, Ait Benali S. Neuroinvasion, neurotropic, and neuroinflammatory events of SARS-CoV-2: understanding the neurological manifestations in COVID-19 patients. *Neurol Sci.* 2020;41(10):2657-69. doi: 10.1007/s10072-020-04575-3.
10. Aghagholi G, Gallo Marin B, Katchur NJ, Chaves-Sell F, Asaad WF, Murphy SA. Neurological involvement in COVID-19 and potential mechanisms: a review. *Neurocrit Care.* 2020;1-10. doi: 10.1007/s12028-020-01049-4.
11. Parsay S, Vosoughi A, Khabbaz A, Sadigh-Eteghad S. The incidence and mortality ratio of ischemic cerebrovascular accidents in COVID-19 cases: a systematic review and meta-analysis. *J Stroke Cerebrovasc Dis.* 2021;30(3):105552. doi: 10.1016/j.jstrokecerebrovasdis.2020.105552.
12. Khosraviani S, Paybast S, Emami A. Encephalitis as a rare manifestation of novel COVID-19 disease, a para-infection or postinfection complication: a systematic review. *Rom J Neurol.* 2020;19(3):153-60.
13. Zhou H, Lu S, Chen J, Wei N, Wang D, Lyu H, et al. The landscape of cognitive function in recovered COVID-19 patients. *J Psychiatr Res.* 2020;129:98-102. doi: 10.1016/j.jpsychires.2020.06.022.
14. Young MJ, O'Hare M, Matiello M, Schmahmann JD. Creutzfeldt-Jakob disease in a man with COVID-19: SARS-CoV-2-accelerated neurodegeneration? *Brain Behav Immun.* 2020;89:601-3. doi: 10.1016/j.bbi.2020.07.007.
15. Sikorska B, Knight R, Ironside JW, Liberski PP. Creutzfeldt-Jakob disease. *Adv Exp Med Biol.* 2012;724:76-90. doi: 10.1007/978-1-4614-0653-2\_6.
16. Vacca VM Jr. CJD: Understanding Creutzfeldt-Jakob disease. *Nursing.* 2016;46(3):36-42. doi: 10.1097/01.NURSE.0000480598.84274.0f.

17. Zerr I, Kallenberg K, Summers DM, Romero C, Taratuto A, Heinemann U, et al. Updated clinical diagnostic criteria for sporadic Creutzfeldt-Jakob disease. *Brain*. 2009;132(Pt 10):2659-68. doi: 10.1093/brain/awp191.
18. Schmidt H, Otto M, Niedmann P, Cepek L, Schröter A, Kretzschmar HA, et al. CSF lactate dehydrogenase activity in patients with Creutzfeldt-Jakob disease exceeds that in other dementias. *Dement Geriatr Cogn Disord*. 2004;17(3):204-6. doi: 10.1159/000076357.
19. Geschwind MD. Rapidly progressive dementia. *Continuum (Minneap Minn)*. 2016;22(2 Dementia):510-37. doi: 10.1212/con.0000000000000319.
20. Donaldson DS, Bradford BM, Else KJ, Mabbott NA. Accelerated onset of CNS prion disease in mice co-infected with a gastrointestinal helminth pathogen during the preclinical phase. *Sci Rep*. 2020;10(1):4554. doi: 10.1038/s41598-020-61483-4.
21. Merad M, Martin JC. Pathological inflammation in patients with COVID-19: a key role for monocytes and macrophages. *Nat Rev Immunol*. 2020;20(6):355-62. doi: 10.1038/s41577-020-0331-4.