



## **A Rare and Challenging Patient of Infantile Haemangioma: Case Report**

**Ashish Ramesh Varma<sup>1</sup>, Anuj Ramesh Varma<sup>1</sup>, Waqar M. Naqvi<sup>2</sup>,  
Tanvi Shashank Banait<sup>1</sup>, Shreyashee Sunil Shinde<sup>1</sup>  
and Om Chandrakant Wadhokar<sup>2\*</sup>**

<sup>1</sup>Jawaharlal Nehru Medical College, Datta Meghe Institute of Medical Sciences, Sawangi, Wardha, India.

<sup>2</sup>Ravi Nair Physiotherapy College, Datta Meghe Institute of Medical Sciences, Sawangi, Wardha, India.

### **Authors' contributions**

*This work was carried out in collaboration among all authors. All authors read and approved the final manuscript.*

### **Article Information**

DOI: 10.9734/JPRI/2021/v33i46A32881

Editor(s):

(1) Dr. Amal Hegazi Ahmed Elrefaei, Hot Lab and Waste Management Center, Atomic Energy Authority, Egypt.

Reviewers:

(1) Varunkumar J, Dr. Vaishampayan Memorial Government Medical College, India.

(2) B. Manovijay, Vinayaka Missions Sankarachariyar Dental College, Vinayaka Mission's Research Foundation, India.

Complete Peer review History: <https://www.sdiarticle4.com/review-history/73874>

**Case Study**

**Received 10 July 2021**  
**Accepted 16 September 2021**  
**Published 15 October 2021**

### **ABSTRACT**

Infantile haemangioma is a condition seen in premature babies, it develops as a birth mark that grows in size commonly seen on back, chest, scalp, the swelling is characterised by bleeding or oozing. In such patients primary concern is any ill effects due to medical condition and secondary concern is cosmetic. A 9 month old baby brought to the hospital with complaints of swelling on the back with oozing. The patient was given IV propranolol for 1 year. And wound care was taught along with ergonomic education for ADLS. The study suggests that the use of IV propranolol shows significant reduction in the swelling and oozing from the swelling.

**Keywords:** *Infantile haemangioma; propranolol; non surgical treatment; case report.*

## 1. INTRODUCTION

Infantile haemangioma previously known as strawberry birth mark is a soft raised swelling on the skin, the prevalence of infantile haemangioma is 3%-10%, these benign vascular tumours are commonly uncomplicated and tend to regress with time. However when haemangion occurs in sensitive areas, such as near eyes, nose or throat may lead to complication [1]. It is commonly seen on face, scalp, back, and chest. Most of the time haemangioma interfere with vision and other symptoms like bleeding from the birthmark [2]. However the complications are least when it develops on the common sites like chest, scalp, back, this benign tumours are characterized by swelling, redness, oozing, such fibrofatty tissue formation hampers the infants psychosocial development [3].

The tumors formation leads to significant behavioral changes in mental health of infant during sensitive period of patient's life. The primary complication of tumors when at life threatening location is functional impairment, visceral involvement. The secondary complications are concerning physical appearance. The frequency of infantile haemangioma is higher in female than male infants with an racial predilection for Caucasians, low birth weight is appears to be the major risk factor with 40% increase in risk for every 500 gram decrease in birth weight [4]. This report is done to find out the systemic effect and remission duration of haemangioma using systemic propranolol.

### 1.1 Patient Information

A 9 month old female child brought with complaints of swelling over the back since child was 1 month of age.

As narrated by father child was apparently alright till 1 month of age when mother had noticed development of swelling over back, initially it was of size of a pea and then gradually progressed in size and attained the present size over time and child had developed ulcer over the swelling 1 month back (Fig. 1A, and Fig. 1B). History of bleeding and white discharge from the ulcer present. Patient was taken to a local private practitioner where they were advised surgery and was referred to Hospital for further management.

### 1.2 Clinical Findings

On admission child was vitally stable with HR-102/min, RR-24/min, peripheral pulses-well felt, spo<sub>2</sub>-99%. Systemic examination is within normal limits.

**On local examination of the swelling:** On Inspection: A single round swelling of size 7\*7cm is seen over the back at the supra scapular area, signs of inflammation present, redness present, skin around the swelling also shows redness, An ulcer of size 5\*5 cm is seen at the centre of the swelling.

On Palpation- All inspector findings confirmed on palpation, soft in consistency, slip sign positive.

On auscultation- No bruit heard over the swelling.

### 1.3 Timeline

Diagnosed with a pea shaped nodule on the back 8/1/2019

Diagnosed with Haemangioma 9/2/2019

Discharge 16/4/2019

Follow up 1 (observation of the swelling) 5/6/2019

Follow up 2 (observation of the swelling) 10/9/2019

### 1.4 Diagnostic Assessment

Patient was admitted in the ward and baseline work up was done suggestive of CBC-Hb-9.2g%, TLC-17400, platelets-5.74, MCV-68.8, LFT, KFT-normal and patient was started on oral antibiotics augmenting.

USG local site- was done suggestive of heterogeneous lesion of size approximately 50\*30mm is noted in the subcutaneous plane of nape of the neck showing multiple vessels with slow flow? VASCULAR MALFORMATION and advised MRI with contrast for further evaluation (Fig. 2).

MRI neck with contrast and MRA- was done suggestive of well defined homogenously enhancing lobulated mass lesion extending from lower end plate of C4 up to upper end plate of D5 with altered signal intensity showing low signal intensity on T1, heterogeneously high signal intensity on T2 with flow voids visualised on all sequences f/s/o INFANTILE HEMANGIOMA (Fig. 3).

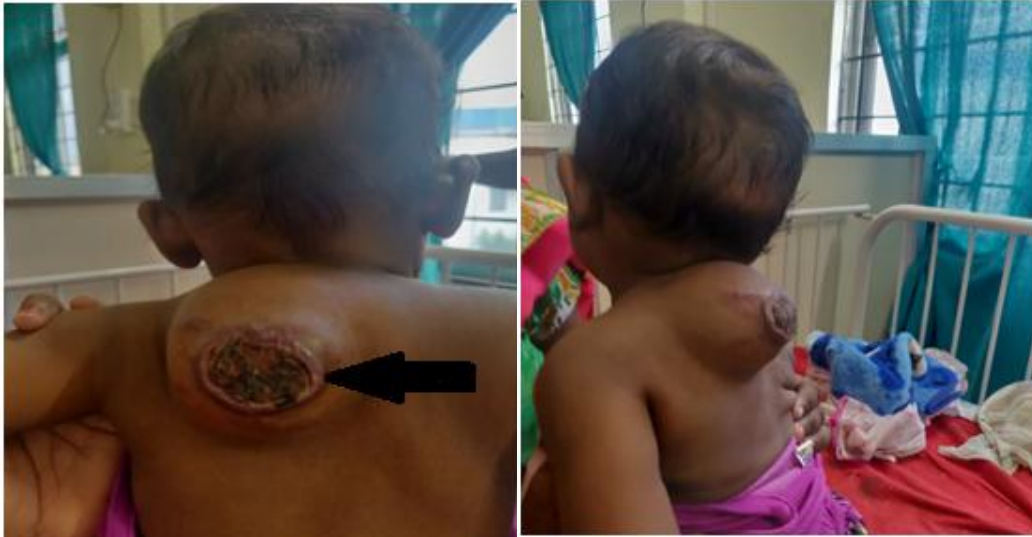

Fig. 1A

Fig. 1B

Fig. 1. Swelling over the back

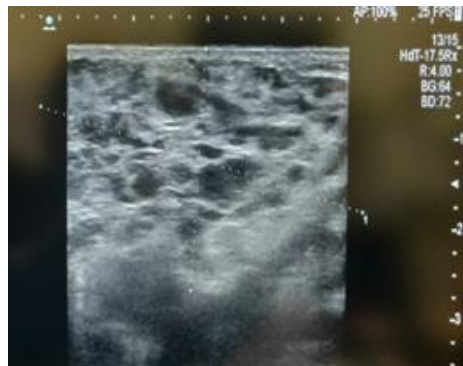

Fig. 2. Vascular malformation and advised MRI with contrast for further evaluation

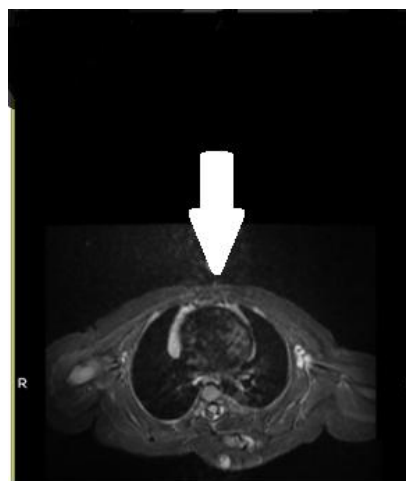
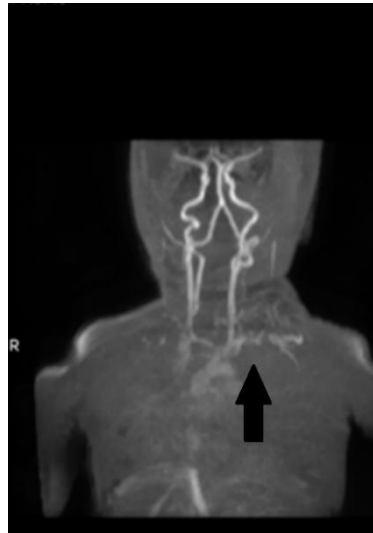

Fig. 3. High signal intensity on T2 with flow voids visualised on all sequences f/s/o INFANTILE HEMANGIOMA



**Fig. 4. MRA- reveals possible feeding artery arising from pre-foraminal segment of left vertebral artery (V1 segment)**

## 2. THERAPEUTIC INTERVENTION

The patient's consent was taken. Opinion from paediatric surgeon was taken and patient was started with injection of ceftriaxone and tablet Ciplar (propranolol) 2 mg/kg/day for one year and was kept under observations and wound care, such as keep the wound dry avoid infection if any noted inform immediately taught to the parents of the patient, and proper ergonomic advice was given to the patient for proper sleeping and ADLs.

## 3. DISCUSSION

A study was done on a patient with haemangioma which showed a multidisciplinary approach is required for remission and prevention of secondary complications. Oral propranolol has significant good results and is now first line of treatment along with topical beta blockers to improve superficial lesion. Other drugs used were steroids [5]. A meta analysis was done by Zhunag Liu et al. On previous studies the clinical outcomes including recovery rate and haemangioma activity score (HAS), adverse effects and relapse rate were compared on patients treated with atenolol and propranolol for infantile haemangioma. The group treated with atenolol has better score on HAS as compared to propranolol. Patient treated with propranolol has more adverse reaction and higher relapse rate. Results suggest that

atenolol is not inferior to propranolol and may offer advantage with lower adverse reaction and relapse rate [6]. A retrospective review of medical records was done on paediatric patient with haemangioma with propranolol. 88 patients with infantile haemangioma was treated with propranolol. This gives further proof of efficacy and safety of propranolol in treating infantile haemangioma (IH) [7]. One study conducted by Kirithi Koka, Bhupendra C. Patel says that these lesions have predictable life cycle and usually does not require any treatment in absence of complications [8]. A study was conducted by Isabel Betlloch-Mas et al. On paediatric population with haemangioma for comparing the effect of teledermatology over propranolol which shows teledermatology was more effective as compared to propranolol [9]. A study conducted by Carol Erin Cheng et al showed that use of topical agents along with surgical interventions such as laser showed better results [10].

## 4. CONCLUSION

To conclude, the child with hemangioma showed positive response, suggesting that use of beta blockers improved patient condition by reducing swelling (Fig. 5A and Fig. 5B). And proper wound care prevent development of the infection and education regarding ADLs improved the condition. Further studies should be conducted to find out the drugs with least or no ill effects.

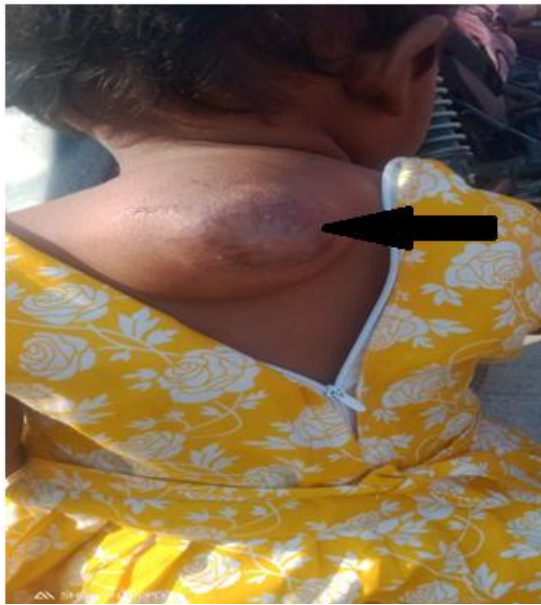

Fig. 5A



Fig. 5B

Fig. 5. Improved patient condition by reducing swelling

## CONSENT

As per international standard, parental written consent has been collected and preserved by the author(s).

## ETHICAL APPROVAL

As per international standard or university standard written ethical approval has been collected and preserved by the author(s).

## COMPETING INTERESTS

Authors have declared that no competing interests exist.

## REFERENCES

1. Novoa M, Baselga E, Beltran S, Giraldo L, Shahbaz A, Pardo-Hernandez H, et al. Interventions for infantile haemangiomas of the skin. *Cochrane Database Syst Rev*. 2018;4:CD006545.
2. Akinbiyi T, Jackson OA, Nguyen PD, Low DW. A Novel Approach in the Surgical Management of Nasal Tip Hemangiomas: A 26-Year Experience. *Plast Reconstr Surg*. 2020;146(6):1348–1351.
3. Ying H, Han Y, Chen Z, Yu Z, Chang L, Ma G, et al. The effect of 0.5% topical timolol cream on regression of superficial infantile haemangioma in the involuting phase: a prospective, randomized, self-controlled study. *Eur J Dermatol EJD*. 2020;30(5):591–595.
4. Wang D, Hu B, Hu C, Zhu F, Liu X, Zhang J, et al. Clinical Characteristics of 138 Hospitalized Patients With 2019 Novel Coronavirus–Infected Pneumonia in Wuhan, China. *JAMA*. 2020;323(11):1061–1069.
5. Srinivasan J, Wells L, Ravenscroft J. Management of infantile haemangioma. *Paediatr Child Health*. 2019;29(2):59–65.
6. Z L, C W, D S, L W, J L, C W, et al. Atenolol vs. propranolol for the treatment of infantile haemangiomas: A systematic review and meta-analysis. *Experimental and therapeutic medicine*. 2020;20(2). DOI:10.3892/etm.2020.8842.
7. Jmc T, Hw L, Mj K. Oral propranolol for the treatment of infantile haemangiomas in Singapore. *Singapore Medical Journal*; 2020. DOI:10.11622/smedj.2020008.
8. Koka K, Patel BC. Capillary Infantile Hemangiomas. In: *Stat Pearls*. 2020. Treasure Island (FL). Stat Pearls. Available: <http://www.ncbi.nlm.nih.gov/books/NBK538249/>. Accessed 1 December 2020.
9. I B-M, Mt M-M, L B-D, L S-V, J S-P. *Teledermatology in paediatrics: Health-*

- care impact on the early treatment of infantile haemangiomas. Journal of telemedicine and telecare; 2020. DOI: 10.1177/1357633X20904901.
10. Cheng CE, Friedlander SF. Infantile hemangiomas, complications and treatments. Semin Cutan Med Surg. 2016; 35(3):108–116.

---

© 2021 Varma et al.; This is an Open Access article distributed under the terms of the Creative Commons Attribution License (<http://creativecommons.org/licenses/by/4.0>), which permits unrestricted use, distribution, and reproduction in any medium, provided the original work is properly cited.

*Peer-review history:*

*The peer review history for this paper can be accessed here:*

*<https://www.sdiarticle4.com/review-history/73874>*