



# ***Azadirachta indica* (Neem) Leaf Extract Effect as an Option of Treatment of Ibuprofen-induced Nephrotoxicity**

**Ifeanacho Ezeteonu Abireh<sup>1\*</sup>, Onyinye Mary Ozioko<sup>1</sup>, Ignatius Ikemefuna Ozor<sup>1</sup>, Elizabeth Finbarrs-Bello<sup>1</sup>, Uche Sebastine Ozioko<sup>1</sup> and Franklin Egbo<sup>1</sup>**

<sup>1</sup>*Department of Anatomy, College of Medicine, Enugu State University of Science and Technology, Nigeria.*

## **Authors' contributions**

*This work was carried out in collaboration among all authors. Author IEA designed the study, performed the statistical analysis, wrote the protocol and wrote the first draft of the manuscript. Author OMO contributed in the writing of the manuscript. Authors IIO and EFB managed the analyses of the study. Authors USO and FE managed the literature searches. All authors read and approved the final manuscript.*

## **Article Information**

DOI: 10.9734/JAMMR/2020/v32i1130533

### Editor(s):

(1) Dr. Emmanouil (Manolis) Magiorkinis, Thoracic Diseases General Hospital Sotiria, Greece.

### Reviewers:

(1) Tarak R. Nadella, Krishna University, India.

(2) Fatima Del Muro Casas, Autonomus University of Zacatecas, Mexico.

Complete Peer review History: <http://www.sdiarticle4.com/review-history/59153>

**Original Research Article**

**Received 06 May 2020**

**Accepted 11 July 2020**

**Published 25 July 2020**

## **ABSTRACT**

**Aim:** This study investigated the curative effect of the aqueous leaf extract of *Azadirachta indica* on Ibuprofen-induced nephrotoxicity in Wistar rat

**Study Design:** This is an experimental research

**Place of Research:** Department of Anatomy, College of Medicine, Enugu State University of Science and Technology.

**Methodology:** Twenty-four male Wistar rats were divided into 6 groups, with 4 rats in each group. Group 1 was control and received oral normal saline 0.5 ml daily. Group 2-6 had induction of nephrotoxicity using oral Ibuprofen 400 mg/Kg daily for 5 days. Group 3-5 were subsequently treated with gavage *Azadirachta indica* leaf extract 200 mg/Kg, 400 mg/Kg and 800 mg/Kg, respectively, for 5 days. And Group 6 was treated with oral Vitamin E 1000 iu/kg for 5 days.

\*Corresponding author: E-mail: ifeanachoabireh@gmail.com;

**Results:** Ibuprofen induced nephrotoxicity as evidenced by elevation of serum creatinine level in group 2 ( $1.99 \pm 0.83$ ), when compared to  $0.48 \pm 0.07$  obtained in group 1 (control), and Bowman's capsule enlargement with glomerular degeneration observed in group 2. The serum creatinine levels progressively approached the level of that of the control in groups treated with *Azadirachta indica* leaf extract, groups 3 ( $1.69 \pm 0.52$ ), 4 ( $0.69 \pm 0.10$ ) and 5 ( $0.49 \pm 0.10$ ). Also, the histoarchitecture progressively normalized to that of control with each increase in dose of the extract.

**Conclusion:** *Azadirachta indica* (neem) leaf extract administration led to the resolution of Ibuprofen-induced kidney injury in this study. Thus, it can serve as a treatment option for kidney injury resulting from ingestion of Ibuprofen, after the identification of the molecule responsible for this effect.

**Keywords:** *Ibuprofen*; *nephrotoxicity*; *neem*; *Azadirachta indica*.

## 1. INTRODUCTION

Non-steroidal anti-inflammatory drugs (NSAIDs) are frequently used analgesics, antipyretics and anti-inflammatory agents [1]. Ibuprofen is a member of these NSAIDs family, and it is effective, cheap, and it is among the commonly prescribed non-steroidal anti-inflammatory drugs [2,3]. Ibuprofen is not without side effects, as this include gastritis, gastric ulceration, hepatotoxicity, nephrotoxicity among others [4]. Drug toxicity accounts for about 33% of cases of acute kidney injury and it usually presents with acute renal failure, tubulopathies, and glomerulopathies [5]. This side effects may hinder the optimal use of this efficacious drug, Ibuprofen. Ibuprofen is an over the counter drug and could be purchased and used without restriction. Some persons have been found to use high doses of Ibuprofen to control pain, especially trauma patients [6].

*Azadirachta indica*, commonly known as Neem, is mainly cultivated in the Indian subcontinent [7,8]. Almost all of the parts of this tree have been used as traditional remedy against different kinds of diseases affecting humans [9]. It is being used traditionally as treatment for gastrointestinal upsets, diarrhoea, skin ulcers and malaria [10]. Studies have shown that its chemical compositions include salannin, volatile oils, meliantriol and nimbin, alkaloids, flavonoids, triterpenoids, phenolic compounds, carotenoids, steroids and ketones [11]. And that it has antioxidant, anti-inflammatory, antibacterial, antifungal, and even antiulcer effects [12]. This study aims to investigate the curative effect of the aqueous leaf extract of *Azadirachta indica* on nephrotoxicity induced by ibuprofen in Wistar rat.

## 2. MATERIALS AND METHODS

### 2.1 Collection and Authentication of Plant Material

The leaves of *Azadirachta indica* were collected from *Azadirachta indica* tree in Enugu metropolis and identified in the department of Botany, Enugu State University of Science and Technology, Enugu.

### 2.2 Preparation of Extract

The leaves of *Azadirachta indica* were washed with distilled water after removal of the stalks, and air dried under shade at room temperature. The leaves were then pulverized to fine powdered form and was then sieved using sieve with little pores to remove the ungrounded fibres. About 1000 g of the powdered form was extracted exhaustively using water. The extract was filtered with Whatman filter paper size 2. The filtrate was then evaporated using water bath. The extract was then kept in the refrigerator at 4°C until it was used for the experiment [13].

### 2.3 Animal Management and Grouping

Twenty-four adult male Wistar rats, with average weight of 150 g were used for this experiment. The animals were handled according to the guideline of the Committee for the purpose of control and supervision of experiments on Animals, India. They were housed in netted iron cages and kept under standard laboratory conditions, with temperature of 25°C, humidity of 60-70% and 12 hours light and dark cycles throughout the experiment. They were randomly selected and divided into (6) groups, groups 1-6, with four (4) rats in each group. And then kept for fourteen days for laboratory adaptation, while having free access to feeds (growers mesh) and

water. Body weight of animals were obtained using Sansa electronic weighing scale before and after laboratory adaptation, and also at weekly intervals throughout the period of the experiment [14].

### 2.4 Nephrotoxicity Induction

Nephrotoxicity was induced in groups 2-6, using 400 mg/kg daily for 5 days [15].

### 2.5 Administration of Extract

Group 1 received oral normal saline 0.5 ml daily for 10 days.

Group 2 had nephrotoxicity induction using oral Ibuprofen 400 mg/kg daily for 5 days.

Group 3-5 had nephrotoxicity induction using oral Ibuprofen 400 mg/kg daily for 5 days. And then treated with gavage *Azadirachta indica* leaf extract 200 mg/kg, 400 mg/kg and 800 mg/kg, respectively, for 5 days.

Group 6 had nephrotoxicity induction using oral Ibuprofen 400 mg/kg daily for 5 days. And then treated with oral Vitamin E 1000 iu/kg daily for 5 days.

### 2.6 Sample Collection

On day 11, the experimental animals were anaesthetized by chloroform inhalation. And blood samples were collected via ophthalmic vessels and immediately transferred into a plain bottle. And subsequently, the animals were sacrificed, and the kidneys excised and immediately transferred into a specimen container containing formal saline.

### 2.7 Sample Analysis

The histological slides of the kidney specimens were prepared using the standard histological techniques with Haematoxylin and Eosin stains. The slides were analyzed using light microscope.

The specimens for serum urea and creatinine were analyzed using Cobas autoanalyzer.

### 2.8 Statistical Analysis

This was done using Statistical Package for Social Sciences (SPSS) version 21. *P*-value of 0.05 or less was considered significant.

## 3. RESULTS

### 3.1 Results of Serum Creatinine and Urea

The serum creatinine was markedly elevated above the control (group 1) from  $0.48 \pm 0.07$  for control to  $1.99 \pm 0.83$ , in the experimental animal group 2, which had nephrotoxicity induced using oral Ibuprofen 400 mg/Kg daily for 5 days, with *P*= .027, as shown in Table 1. However, when the *Azadirachta indica* leaf extract was administered to the animals after induction of nephrotoxicity, the serum creatinine level in these groups (3, 4 and 5) were observed to approach that of the control, with the values being  $1.69 \pm 0.52$ ,  $0.69 \pm 0.10$  and  $0.49 \pm 0.10$ , respectively. Group 6, which received 1000 iu/kg of Vitamin E also had serum creatinine level ( $0.70 \pm 0.00$ ) close that of the control as shown in Table 1.

### 3.2 Histological Analysis

The histology of the kidney in group 1, which received 0.5 ml normal saline throughout the period of the experiment shows normal renal histoarchitecture. The glomeruli and Bowman's capsules were surrounded by numerous renal tubules. They had normal renal corpuscle with typical cellular delineation, distribution, density and staining intensity. There was no apparent histopathological alteration, as shown in Fig 1. The histology of the experimental animals in group 2, which had nephrotoxicity induced with Ibuprofen 400 mg/kg, shows corpuscular degeneration, and shrunken glomeruli, as shown in Fig. 2. These effects suggest pathological alteration. The histology of the experimental

**Chart 1. Administration of extract**

Days	1-5	6-10
GROUP 1	Normal saline 0.5 ml daily	Normal saline 0.5 ml daily
GROUP 2	Ibuprofen 400 mg/kg daily	Ibuprofen 400 mg/kg daily
GROUP 3	Ibuprofen 400 mg/kg daily	Extract 200 mg/kg daily
GROUP 4	Ibuprofen 400 mg/kg daily	Extract 400 mg/kg daily
GROUP 5	Ibuprofen 400 mg/kg daily	Extract 800 mg/kg daily
GROUP 6	Ibuprofen 400 mg/kg daily	Vitamin E 1000 iu/kg daily

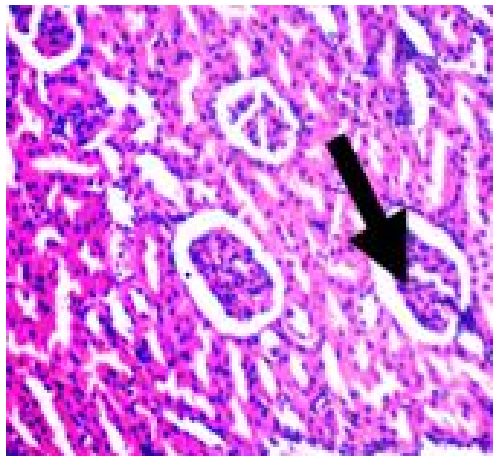
animals in group 3, which received *Azadirachta indica* leaf extract 200 mg/kg shows few renal corpuscles, numerous dilated convoluted tubule, but with normal Bowman’s space and glomeruli, as shown in Fig. 3. Group 4 received *Azadirachta indica* leaf extract 400 mg/kg, and the histology shows normal renal corpuscle with typical cellular delineation, distribution, density and staining intensity. No apparent histopathological alteration (Fig. 4). The histology of the group 5, that received *Azadirachta indica* leaf extract 800mg/kg following induction of nephrotoxicity, shows typical cellular delineation, distribution, density and staining intensity, with some areas of corpuscular degeneration, as shown in Fig. 5. Group 6 received Vitamin E 1000 iu/Kg and also shows normal renal corpuscle with typical cellular delineation, distribution, density and staining intensity, as shown in Fig. 6.

**Table 1. serum creatinine and urea**

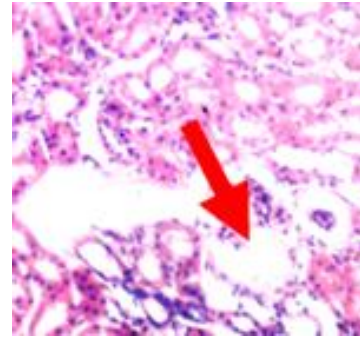
Groups	Creatinine (mg/dL)	Urea (mg/dL)
1	0.48±0.07	46.76±0.15
2	1.99±0.83*	57.50±1.42
3	1.69±0.52	55.27±0.24
4	0.69±0.10	47.74±1.33
5	0.49±0.10	46.83±0.25
6	0.70±0.00	47.26±1.01

*P*=0.027; *P*=0.087

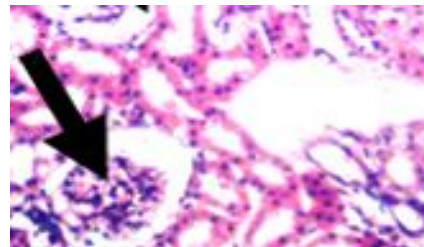
Values were expressed as Mean± SD. Where \**P*<0.05 showed a significant difference compared to group 1 while those without superscript showed no significant difference (*P*>0.05) using One- way anova with Tukey HSD test for multiple comparison



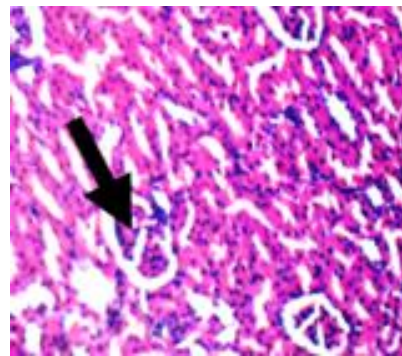
**Fig. 1. Photomicrograph section (x100) of the kidney of experimental animal following administration of oral normal saline 0.5 ml for 10 days. shows normal renal histoarchitecture. Arrow shows a glomerulus**



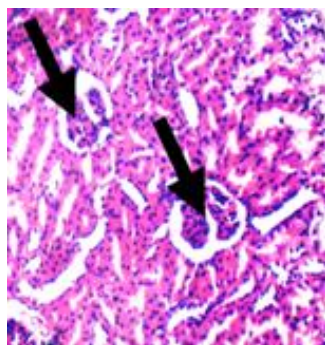
**Fig. 2. Photomicrograph section (x100) of the kidney of experimental animal following administration oral ibuprofen 400 mg/kg daily for 5 days. Shows corpuscular degeneration as indicated by the arrow**



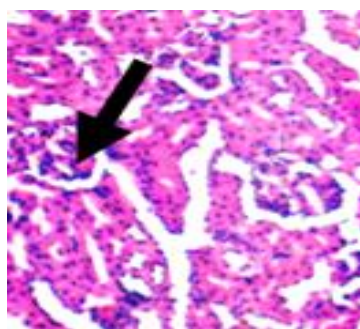
**Fig. 3. Photomicrograph section (x100) of the kidney of experimental animal following administration oral ibuprofen 400 mg/kg daily for 5 days. And then leaf extract of *Azadirachta indica* 200 mg/kg. Shows a shrunken glomerus (arrow) and a bowman’s capsule with glomerulus. Also shows a bowman’s capsule without a glomerus**



**Fig. 4. Photomicrograph section (x100) of the kidney of experimental animal following administration oral ibuprofen 400 mg/kg daily for 5 days. And then leaf extract of *Azadirachta indica* 400 mg/kg. Arrow shows a glomerulus with features close to that of the control**



**Fig. 5. Photomicrograph section (x100) of the kidney of experimental animal following administration oral ibuprofen 400 mg/kg daily for 5 days. And then leaf extract of Azadirachta indica 400 mg/kg. Arrow shows a glomerulus with features similar to that of the control**



**Fig. 6. Photomicrograph section (x100) of the kidney of experimental animal following administration oral ibuprofen 400 mg/kg daily for 5 days. And then oral vitamin E 1000 iu/kg daily for 5 days. Shows mild shrinkage of the glomeruli**

#### 4. DISCUSSION

Acute kidney injury caused by non-steroidal anti-inflammatory drugs, such as Ibuprofen, is due to reduced renal blood flow caused by a decrease in prostaglandins. Prostaglandins regulate vasodilation at the level of the glomerulus. So, these agents, non-steroidal anti-inflammatory drugs disrupt the compensatory vasodilation response of renal prostaglandins to vasoconstrictor effects of some hormones released by the body [16]. The inhibition of renal prostaglandins as a result of Ibuprofen ingestion results in acute deterioration of renal function. Non-steroidal anti-inflammatory agents can also cause acute interstitial nephritis, which is characterized by the presence of inflammatory

cells infiltrate in the interstitium of the kidney, and may result in acute kidney injury [17].

Urea and creatinine are metabolic waste products that are freely filtered by the glomeruli of the kidneys [18]. Their serum concentrations are widely used as markers of renal function [19,20]. The values are elevated in renal toxicities or in situations with abnormal renal function. The experimental animals that had renal toxicity induced with Ibuprofen, and without treatment with the extract (group 2) showed a significant increase ( $P=.027$ ) in serum creatinine level when compared to those in group 1, that received normal saline only (Table 1). These findings correlate with the study by Jonah and colleagues [21]. Histological analysis of the control group (group 1) shows a normal renal architecture as shown in Fig. 1. Following induction of nephrotoxicity using oral Ibuprofen in group 2 of the experimental animals, there were marked widespread corpuscular degeneration and dilatation of the Bowman's capsule, as shown in Fig. 2. This signifies pathological alteration when compared to group 1, which got normal saline only, throughout the experiment. This corroborates previous findings that ibuprofen induces nephrotoxicity at high doses [15,22]. This significant increase in serum level of creatinine and the widespread Bowman's capsule dilatation and glomerular degenerations supposes that the Ibuprofen causes significant kidney injury when taken at high doses.

The experimental animals with induced renal toxicity and treatment with low dose of aqueous leave extract of *Azadirachta indica* (group 3) had few numbers of renal corpuscles due to glomerular regeneration. They also had numerous dilated convoluted tubules and dilated Bowman's space, as shown in Fig. 3, but not as much as that seen in group 2, which is the group that did not receive extract in addition to the ibuprofen. The serum creatinine level was also elevated when compared to that of group 1, as shown in Table 1, but this serum creatinine level is not as high as that seen in the animals in group 2. This shows that there is an attempt at healing in this group. Significant healing process was noticed in Fig. 4, which is the photomicrograph of the group treated with 400 mg/kg of leaf extract after induction of renal toxicity with Ibuprofen. Fig. 4 shows normal renal corpuscle with typical cellular delineation, distribution and density. The creatinine level of the experimental animals in this group showed no significant difference when compared to group

1, as shown in Table 1. The renal architecture in this group was restored, signifying that the nephrotoxicity was effectively cured. From these observations, it can be deduced that *Azadirachta indica* leaf extract reverses nephrotoxicity. This was also observed by Ezz-Din and colleagues [23]. However, the results of the animals in group 5, that is, those treated with 800mg/kg of leaf extract after induction of renal toxicity with Ibuprofen, showed varying histoarchitecture, with some normal renal corpuscles and some dilated Bowman's capsule and mildly shrunken glomerulus, as shown in Fig. 5. This suggests that the leaf extract of *Azadirachta indica* may have deleterious effects on the kidney at higher doses. This renal toxicity observed in this study has also been observed in *Azadirachta indica* leaf extract poisoning in patients who abuse it and take it at high dosages [24].

This curative effect of *Azadirachta indica* leaf extract on renal injury may be due to its composition of flavonoids. Flavonoids in *Azadirachta indica* (neem) leaf has both antioxidant and anti-inflammatory activities with resultant inhibition of lipid peroxidation, and scavenging of free radicals [24]. The leaf is also rich in polyphenols, which are known to have antioxidant and free radical scavenging properties [25]. In this study, the group treated with Vitamin E, an antioxidant, after nephrotoxicity induction with Ibuprofen, also showed restoration of renal tissue histoarchitecture, as shown in Fig. 6. It shows normal renal corpuscle with typical cellular delineation, distribution, density and staining intensity, but not as much as the effect seen with *Azadirachta indica*.

## 5. CONCLUSION

This study shows that Ibuprofen, a non-steroidal anti-inflammatory drug can cause renal toxicity at high doses. And that when this toxicity occurs, a remedy can be found in aqueous leaf extract of *Azadirachta indica* (neem) leaves. However, an abuse of this remedy found in neem leaves, by ingestion of high doses, can also result in renal toxicity. This study also shows that Vitamin E, which is an antioxidant can reverse renal toxicity caused by Ibuprofen, albeit to a lesser extent when compared to the leaf extract of *Azadirachta indica* at the doses studied.

## CONSENT

It is not applicable.

## ETHICAL APPROVAL

Ethical clearance for this study was obtained from The Ethical Committee, ESUT College of Medicine.

## COMPETING INTERESTS

Authors have declared that no competing interests exist.

## REFERENCES

1. Meek IL, Van de Laar MA, Vonkeman H. Non-steroidal anti-inflammatory drugs: An overview of cardiovascular risks. *Pharmaceuticals*. 2010;3(7):2146-2162.
2. Burke A, Smyth EM, FitzGerald GA. Analgesic-antipyretic agents: Pharmacotherapy of Gout. In: Brunton LL, Lazo JS, Parker KL. Editors. *Goodman and Gilman's The Pharmacological Basis of Therapeutics*. 11<sup>th</sup> ed. New York: McGraw-Hill. 2006;11:629-651.
3. Aprioku JS, Uche FI. Effects of non-steroidal anti-inflammatory drugs in albino rats. *British Journal of Pharmaceutical Research*. 2013;3(3):314-325.
4. Efrati S, Berman S, Siman-Tov Y, Lotan R, Averbukh Z, Weissgarten J, Golik A. N-acetylcysteine attenuates NSAID-induced rat renal failure by restoring intrarenal prostaglandin synthesis. *Nephrology Dial Transplant*. 2007;22:1873-1881.
5. Sales GTM, Forsesto RD. Drug-induced Nephrotoxicity. *Revista Associacao Medica Brasileira*. 2020;66(1):82-90.
6. Patil S, Subramany S, Patil S, Gurram P, Singh M, Krause M. Ibuprofen Abuse- A case of rhabdomyolysis, hypokalemia and hypophosphataemia with drug-induced mixed renal tubular acidosis. *Kidney International Reports*. 2018;3(5):1237-1238.
7. Puri HS. *Neem: The divine tree*. Amsterdam: Harwood Academic Publishers; 1999.
8. Upma A, Ashok K, Pankaj K, Tarun K. The nature's Gift to mankind: Neem. *International Research Journal of Pharmacy*. 2011;2(10):13-15.
9. Botelho MA, Santos RA, Martins JG, Carvalho CO, Paz MC, Azenha C, et al. Efficacy of A mouth rinse based on leaves of the neem tree (*Azadirachta indica*) in the treatment of patients with chronic gingivitis: A double blind, randomized controlled trial.

- Journal of Medicinal Plant Research. 2008; 2(11):341–346.
10. Schmutterer H. The neem tree: Source of unique natural products for integrated pest management, medicine, industry and other purposes, VCH, Weinheim. 1995;1-696.
  11. Jacobson M. Review of neem research in the United States. In: Locke JC, Lawson RH. Editors. Proceedings of a workshop in neems potential In pest management program. United State Department of Agriculture-Agricultural Research Services. Beltsville. 1990;86:414.
  12. Chaisawangwong W, Gritsanapan W. Quality assessment and scavenging activity of siamese neem flower extract. Natural Product Research. 2013;27(5): 394–401.
  13. Abireh IE, Ozor CC, Mba CE, Finbarrs-Bello E, Atuadu VO, Aliopia EF. Antidote to cyclophosphamide-induced myelosuppression: The *Vitex doniana* leaf effect. IOSR Journal of Dental and Medical Sciences. 2020;19(3):47-50.
  14. Finbarrs-Bello E, Abireh IE, Ude V. *In vitro* therapeutic potential of leaf extract of *Eugenia uniflora* linn on acute inflammation rat model. Journal of Diseases and Medicinal Plants. 2020;6(2):31-38.
  15. Awad DS, Ali RM, Mhaidat NM, Shotar AM. Zizyphus jujube protects against ibuprofen-induced nephrotoxicity in rats. Pharmaceutical Biology. 2014; 52(2):182-186.
  16. Whelton A. Nephrotoxicity of nonsteroidal anti-inflammatory drugs: Physiological foundations and clinical implications. The American Journal of Medicine. 1999;106.
  17. Ulinski T, Guignonis V, Dunan O, Bensman A. Acute renal failure after treatment with nonsteroidal anti-inflammatory drugs. European Journal of Pediatrics. 2004;168:148-150.
  18. Gaspari F, Perico N, Matalone M, Signorini O, Azzollini N, Mister M, Remuzzi G. Precision of plasma clearance of iohexol for estimation of gfr in patients with renal disease. Journal of American Society of Nephrology. 1998;9:310-313.
  19. Perrone R, Madias N, Levy A. Serum creatinine as an index of renal functions: new insight into old concepts. Clinical Chemistry. 1992;38:1933-1953.
  20. Traynor J, Geddes CC, Fox JG. How to measure renal function in clinical practice. British Medical Journal. 2006;333:733-737.
  21. Jonah SA, Lucky LN, Cecilia NA. Evaluation of toxicological profile of ibuprofen in wistar albino rats. American Journal of Biomedical Sciences. 2014; 6(1):32-40.
  22. Mohammed TA. The effect of olive oil on ibuprofen induced renal toxicity in female rats. Kerbala Journal of Pharmaceutical Sciences. 2017;13:5-9.
  23. Ezz-Din D, Gabry MS, Farrag AH, Abdel Moneim AE. Physiological and histological impact of *Azadirachta indica* leaves extract in a rat model of cisplatin-induced hepato and nephrotoxicity. Journal of Medicinal Plant Research. 2011;5(23): 5499-5506.
  24. Brett J, Beresford R, Sevastos J, Day R. Neem extract poisoning as a cause of renal tubular acidosis. Journal of Clinical Toxicology. 2011;1(3):1-3.
  25. Kitdamrongtham W, Ishii K, Ebina K. et al. Limonoids and flavonoids from the flowers of *Azadirachta indica* var. Siamensis and their melanogenesis-inhibitory and cytotoxic activities. Chemistry and Biodiversity. 2014;11(1):73-84.

© 2020 Abireh et al.; This is an Open Access article distributed under the terms of the Creative Commons Attribution License (<http://creativecommons.org/licenses/by/4.0>), which permits unrestricted use, distribution, and reproduction in any medium, provided the original work is properly cited.

**Peer-review history:**

The peer review history for this paper can be accessed here:

<http://www.sdiarticle4.com/review-history/59153>