

Journal of Advances in Medicine and Medical Research

28(7): 1-6, 2018; Article no.JAMMR.45576

ISSN: 2456-8899

(Past name: British Journal of Medicine and Medical Research, Past ISSN: 2231-0614,
NLM ID: 101570965)

IV Administration of Thrombolytic Therapy in a Case with Hemianopsia Symptoms

Cemile Haki¹, Oğuzhan Gümüştas^{2*}, Asuman Ali¹ and Aygül Güneş¹

¹Bursa Yüksek İhtisas Training and Research Hospital Neurology Clinic, Turkey.

²Burtom Radiological Diagnostic Center, Turkey.

Authors' contributions

This work was carried out in collaboration between all authors. All authors read and approved the final manuscript.

Article Information

DOI: 10.9734/JAMMR/2018/45576

Editor(s):

(1) Dr. Ashish Anand, Department of Orthopaedic Surgery, GV Montgomery Veteran Affairs Medical Center, Jackson, MS, USA.

(2) Dr. Chan-Min Liu, School of Life Science, Xuzhou Normal University, Xuzhou City, China.

(3) Dr. Barbara Giambene, Department of Translational Surgery and Medicine, University of Firenze, Italy.

Reviewers:

(1) Adrià Arboix, University of Barcelona, Spain.

(2) Hesna Bektaş Yıldırım, Ankara Yıldırım Beyazıt University, Turkey.

(3) Slaven Pikija, Parazelsus Medical University, Austria.

(4) Luis Rafael Moscote-Salazar, Universidad de Cartagena, Colombia.

(5) Yueh-Feng Sung, National Defense Medical Center, Taiwan.

Complete Peer review History: <http://www.sdiarticle3.com/review-history/45576>

Case Study

Received 09 October 2018

Accepted 28 December 2018

Published 17 January 2019

ABSTRACT

Intravenous thrombolytic therapy is useful also in the treatment of very mild ischemic strokes. The recent FDA guidelines have approved that IV administration of recombinant tissue plasminogen activator (rtPA) should be performed in the cases with NIHSS<5 despite its potential risks. The administration of IV thrombolytic therapy is recommended also in the patients with aphasia or hemianopsia. In routine clinical practice, there is a tendency to avoid thrombolytic therapy in the case with only low NIHSS score, aphasia or hemianopsia to eliminate the potential risks. Hemianopsia may significantly affect the daily life of young and active patients. In this paper, we have reported a case who was brought to emergency service due to the complaint of visual impairment and administered IV thrombolytic therapy for partial homonymous hemianopsia only on the left side detected by neurological examination.

*Corresponding author: E-mail: oggugu@myinet.com;

Keywords: Hemianopsia; thrombolytic therapy; ischemic stroke.

1. INTRODUCTION

Intravenous thrombolytic therapy is useful also in very mild ischemic stroke. The recent FDA guideline has approved that IV administration of recombinant tissue plasminogen activator (rtPA) should be used in the cases with NIHSS<5 despite its potential risks [1]. The guidelines of the American Heart Association/American Stroke Association (AHA/ASA) recommended the administration of rtPA in all the cases only with a measurable neurological deficit such as aphasia and/or hemianopsia [2].

In this paper, we have reported a case who was brought to emergency service due to the complaint of visual impairment and administered IV thrombolytic therapy for partial homonymous hemianopsia only on the left side and acute isolated PCA occlusion detected with neurological examination.

2. CASE

A 60-year-old male patient was brought into the emergency service of our hospital due to the complaint of a sudden onset of visual impairment after alcohol consumption at the 87th minute of his clinical process. His medical history included coronary artery disease and previous coronary artery bypass surgery beside family history including cerebrovascular disease in his father. He was currently using clopidogrel 75 mg/day. His neurological examination revealed no

abnormality except homonymous hemianopsia on the left side. NIHSS score was 2. Arterial blood pressure was 120/80 mmHg. The laboratory test results showed no pathological finding. The Cranial CT showed no pathological finding except an arachnoid cyst localized in the left Sylvian fissure (Image 1). The ASPECT score was 10. The baseline Perfusion CT encountered hypoperfusion in the PCA irrigation area of the right occipital lobe that was not visualized in normal CT (Image 2). A hypodense edematous field suggestive of infarction was encountered in the location compatible with the PCA irrigation area of the right occipital lobe (Image 3). IV thrombolytic therapy (0.9 mg/kg of body weight) was initiated at the 147th minute of his clinic course. The clinical condition of the patient was partially improved after thrombolytic therapy. The patient was evaluated also by The Department of Cardiology with respect to etiological aspects. Atrial fibrillation was detected by ECG. The patient was discharged by initiating Rivaroxaban therapy 20 mg/day and recommended to be followed-up by Stroke Polyclinic. His echocardiographic examination demonstrated left ventricle in normal size and functions, left atrial size of 4.6 cm and presence of mild mitral regurgitation. The patient was discharged 5 days after the admission. The neurological examination on the 3rd month manifested clinically significant improvement in the visual impairment and Goldmann visual field examination revealed a defect at 3rd month.

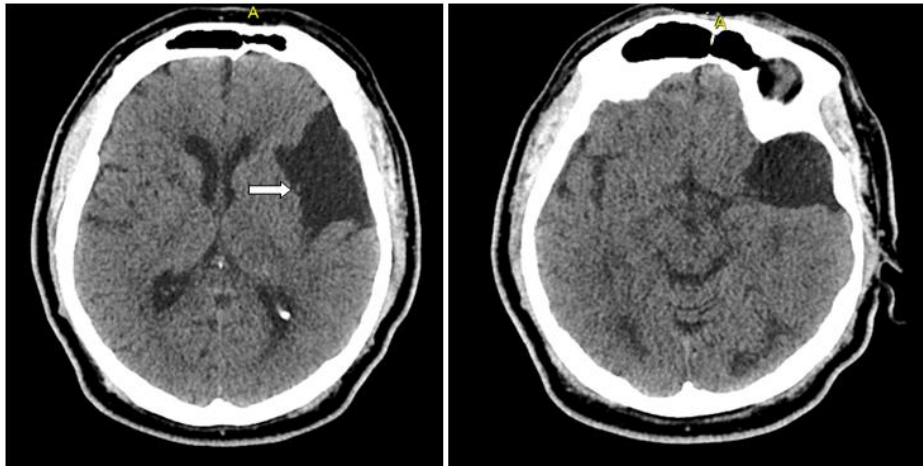


Image 1. The cranial CT showed no pathological finding except an arachnoid cyst in the left sylvian fissure location (arrow), no CT finding compatible with infarct was detected

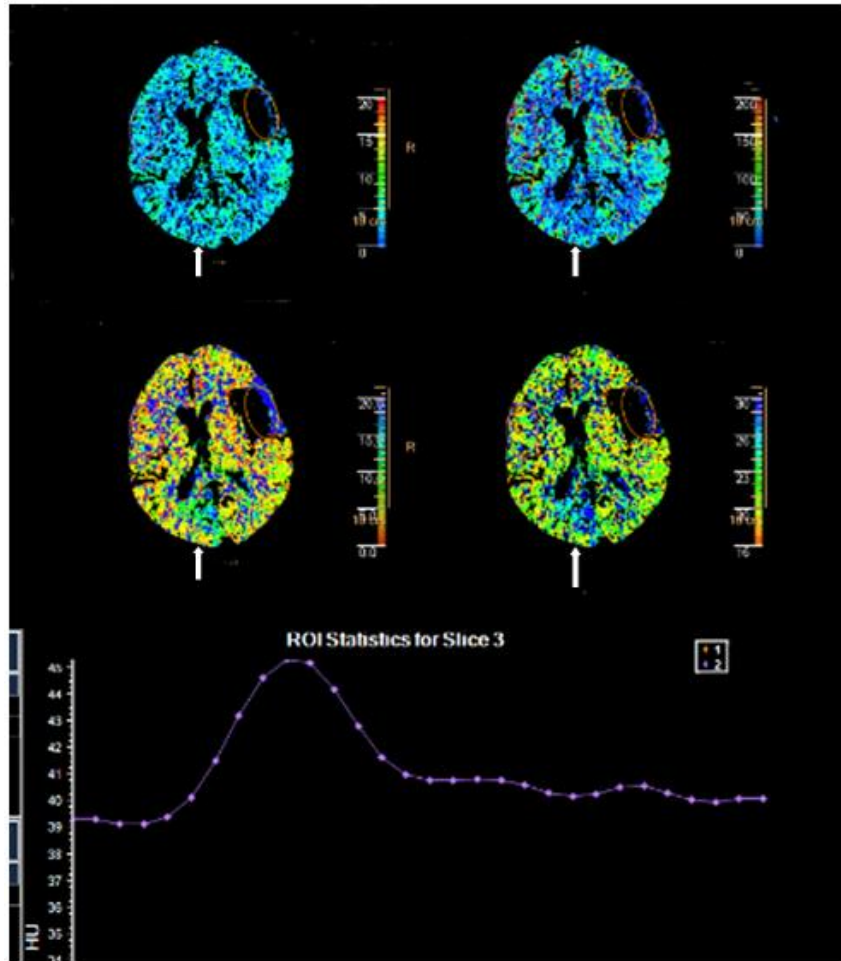


Image 2. Hypoperfusion in the PCA irrigation area of the right occipital lobe that was not visualized in the normal CT was remarkably encountered in the baseline perfusion CT (arrows)

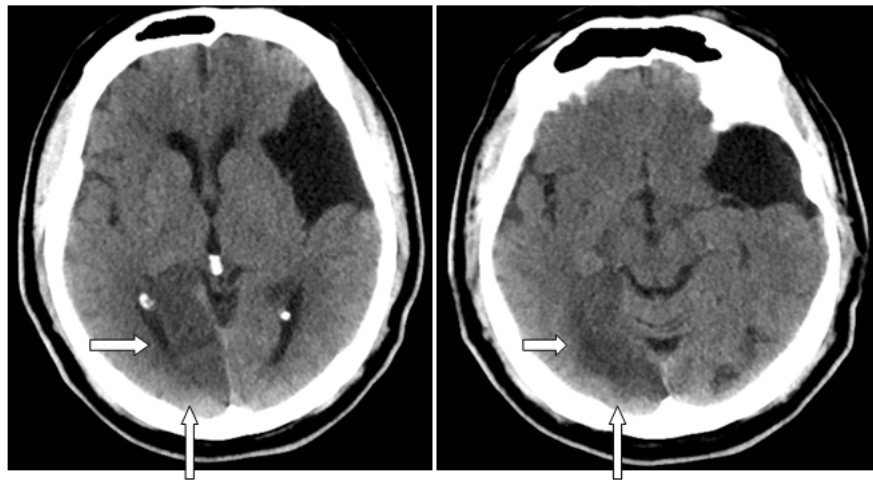


Image 3. The CT images obtained at the 24th hour encountered a hypodense edemateous field suggestive of infarct in the location compatible with the PCA irrigation area of the right occipital lobe (arrows)

3. RESULTS AND DISCUSSION

Cerebral infarctions in the posterior cerebral artery (PCA) region are not rare. Many patients may experience various unidentifiable symptoms at the moment of PCA infarction, as a consequence, they may not describe clear signs and symptoms accurately [3].

The patients may be unaware of the signs and symptoms, consequently diagnosis process may be delayed for administration of intravenous thrombolytic therapy if the patients experience these clinical circumstances for the first time or report in the form of isolated complaints [4].

Hemianopsia make 70% of the cases with visual field losses due to posterior cerebral artery infarctions as the most common anomaly [5]. Homonymous visual field defects may significantly impair visual function. In stroke, the incidence of homonymous visual field defects ranges between 1.1% to 10% [6].

Homonymous hemianopsia is found in 40%, 30% and 25% of the occipital lobe, parietal lobe and temporal lobe lesions, respectively. Furthermore, it is encountered in 5% of the cases with involvement of the visual pathways and lateral geniculate nucleus [4]. Hemianopsia has a considerable importance because it may extremely limit the daily functions and activities such as walking at home or outside, movement, reading, adapting to unfamiliar environment and spaces [5].

In the present case, the patient did not report any complaint or finding except visual field loss. Visual field loss may be caused by trauma, congenital anomalies, tumor and infections as well as stroke. However, ischemia in the posterior cerebral artery irrigation area is responsible for 40-90% of the isolated homonymous visual field losses [6]. In one study, it has been surprisingly reported in a study that only 3 of the 13 patients with a medical history of stroke and with visual field defect were aware of visual field loss [6].

Ischemic strokes involving the PCA region make 5%-10% of all acute ischemic strokes. Lacunar infarctions are the most common subtype of stroke followed by atherothrombotic and cardioembolic infarcts [7,8].

The majority of patients with PCA stroke have a lower NIHSS score than those with stroke of the

middle cerebral artery (MCA) or internal carotid artery (ICA) [9]. The NIHSS score is also very low in hemianopsia; however, it may affect life quality seriously. The time interval from the appearance of visual field loss to definitive diagnosis may be very long in stroke patients; therefore, early detection of visual field loss is very important since the long-term functional outcomes may get worsened in this patient group than other stroke patients [4].

A study of the National Institute of Neurological Disorders and Stroke (NINDS) in 1995 has demonstrated the efficacy of IV thrombolytic therapy within the first 3 hours after acute ischemic stroke [10]. The administration of intravenous r-tPA has been approved by the Food and Drug Administration in 1996 in the USA [11]. The drug has received certification in 2006 to be administered for acute ischemic stroke in Turkey. In the present time, this treatment is recommended within 4.5 hours after the onset of signs and symptoms of acute ischemic stroke [12].

There is few data available for ischemic stroke patients with homonymous hemianopsia who received thrombolytic therapy. Three patients with isolated homonymous hemianopsia were identified among 1427 patients who received thrombolytic therapy and excellent outcomes were reported in all these patients [13]. Breuer et al. [14] have reported the efficacy of thrombolytic therapy in acute ischemic strokes in the PCA region.

The indication for intravenous thrombolytic therapy is based in the presence of a dysfunctioning disorder rather than NIHSS score. Nevertheless, data on safety and efficacy of intravenous thrombolytic therapy in the patients with stroke associated with PCA region support its administration. As a conclusion, the patients without a contraindication should be treated with IV t-PA within 4.5 hours from the onset of signs and symptoms for acute ischemic stroke associated with PCA region [3].

Differential diagnosis of ischemic stroke should absolutely be performed in the cases with. In addition, it has been reported in the recent time that this treatment may be useful in also very mild ischemic strokes. In routine clinical practice, there is a tendency to avoid thrombolytic therapy in the case with only low NIHSS score, aphasia or hemianopsia to eliminate the potential risks.

4. CONCLUSION

We have aimed to present this case with only partial hemianopsia in the neurological examination and NIHSS score of 2 in whom we have administered IV thrombolytic therapy and achieved improvement without a complication. In this case, it is difficult to say whether partial improvement in homonymous hemianopsia was achieved by IV thrombolytic treatment or clinical course of the disease. Hemianopsia may significantly affect the daily life of young and active patients. Thrombolytic therapy is recommended in the cases with only aphasia or hemianopsia.

CONSENT

As per international standard or university standard, patient's written consent has been collected and preserved by the authors.

ETHICAL APPROVAL

It is not applicable.

COMPETING INTERESTS

Authors have declared that no competing interests exist.

REFERENCES

1. Demaerschalk BM, Kleindorfer DO, Adeoye OM, Demchuk AM, Fugate JE, Grotta JC, Khalessi AA, Levy EI, Palesch YY, Prabhakaran S, Saposnik G, Saver JL, Smith EE, American Heart Association Stroke Council and Council on Epidemiology and Prevention. Scientific rationale for the inclusion and exclusion criteria for intravenous alteplase in acute ischemic stroke: A statement for healthcare professionals from the American Heart Association/American Stroke Association. *Stroke*. 2016;47:581-641.
2. Jauch EC, Saver JL, Adams HP Jr, Bruno A, Connors JJ, Demaerschalk BM, Khatri P, McMullan PW Jr, Qureshi AI, Rosenfield K, Scott PA, Summers DR, Wang DZ, Wintermark M, Yonas H, American Heart Association Stroke Council, Council on Cardiovascular Nursing, Council on Peripheral Vascular Disease, Council on Clinical Cardiology. Guidelines for the early management of patients with acute ischemic stroke: A guideline for healthcare professionals from the American Heart Association/American Stroke Association. *Stroke*. 2013;44:870-947.
3. Taiki Yamamoto, Tomotaka Ohshima, Masaki Sato, Shusaku Goto, Kojiro Ishikawa, Toshihisa Nishizawa, Shinji Shimato, Kyoza Kato. A case of acute isolated posterior cerebral artery occlusion successfully treated with endovascular clot aspiration. 2017;4(2):55-58.
4. Zhang X, Kedar S, Lynn MJ, Newman NJ, Biouesse V. Homonymous hemianopias: Clinical-anatomic correlations in 904 cases. *Neurology*. 2006;66:906-10.
5. Nelles G, Widman G, de Greiff A, Meistrowitz A, Dimitrova A, Weber J, et al. Brain representation of hemifield stimulation in poststroke visual field defects. *Stroke*. 2002;33:1286-93.
6. Gilhotra JS, Mitchell P, Healey PR, Cumming RG, Currie J. Homonymous visual field defects and stroke in an older population. *Stroke*. 2002;33:2417-20.
7. Breuer L, Huttner HB, Jentsch K, Blinzler C, Winder K, Engelhorn T, Köhrmann M. Intravenous thrombolysis in posterior cerebral artery infarctions. *Cerebrovasc Dis*. 2011;31:448-454.
8. Arboix A, Arbe G, García-Eroles L, Oliveres M, Parra O, Massons J. Infarctions in the vascular territory of the posterior cerebral artery: Clinical features in 232 patients. *BMC Research Notes*. 2011;4:329.
9. Meier N, Fischer U, Schroth G, Findling O, Brekenfeld C, El-Koussy M, Marchis G, Mono L, Jung S, Gralla J, Nedeltchev K, Mattle H, Arnold M. Outcome after thrombolysis for acute isolated posterior cerebral artery occlusion. *Cerebrovasc Dis*. 2011;32:79-88.
10. National Institute of Neurological Disorders and Stroke rt-PA Stroke Study Group. Tissue plasminogen activator for acute ischemic stroke. *N Engl J Med*. 1995;333:1581-1587.
11. Furlan AJ, Eyding D, Albers GW, Al-Rawi Y, Less KR, Rowley HA, Sachara C, Soehngen M, Warach S, Hacke W; DEDAS Investigators. Dose escalation of Desmoteplase for Acute Ischemic Stroke (DEDAS): Evidence of safety and efficacy

- 3 to 9 hours after stroke onset. Stroke. 2006;37:1227-1231.
12. Lees KR, Bluhmki E, von Kummer R, Brodt TG, Toni D, Grotta JC, Albers GW, Kaste M, Marler JR, Hamilton SA, Tilley BC, Davis SM, Donnan GA, Hacke W; ECASS, ATLANTIS, NINDS and EPITHET rt-PA Study Group, Allen K, Mau J, Meier D, del Zoppo G, De Silva DA, Butcher KS, Parsons MW, Barber PA, Levi C, Bladin C, Byrnes G. Time to treatment with intravenous alteplase and outcome in stroke: an updated pooled analysis of ECASS, ATLANTIS, NINDS and EPITHET trials. Lancet. 2010;375:1695-1703.
 13. Strbian D, Soenne L, Sairanen T, Scheperjans F, Salonen O, Palomäki M, et al. Intravenous thrombolysis in ischemic stroke patients with isolated homonymous hemianopia. Acta Neurol. Scand. 2012; 126:e17–e19.
 14. Breuer L, Huttner HB, Jentsch K, Blinzler C, Winder K, Engelhorn T, Köhrmann M. Intravenous thrombolysis in posterior cerebral artery infarctions. Cerebrovasc Dis. 2011;31:448–454.

© 2018 Haki et al.; This is an Open Access article distributed under the terms of the Creative Commons Attribution License (<http://creativecommons.org/licenses/by/4.0>), which permits unrestricted use, distribution, and reproduction in any medium, provided the original work is properly cited.

Peer-review history:
The peer review history for this paper can be accessed here:
<http://www.sdiarticle3.com/review-history/45576>